



NEWSLETTER

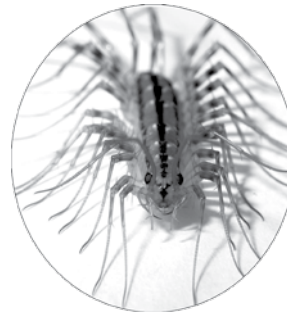
Alumni News of the New York-Presbyterian Hospital/Columbia University Department of Surgery
Volume 11 Number 1 Summer 2008

I Wish You Could Have Been There

Columbia University's Surgical Department hosted the 8th Annual (traditionally rainy) John Jones Surgical Day on May 9, 2008. It was indeed a full day, starting with breakfast in the Donald Tapley Faculty Club, followed by surgical case videos (normally, not my cup of tea – remember “Tea,” it is destined to reappear). Next on the agenda, was a show and tell session with an interesting twist, in Vanderbilt Clinic's 14th floor, George H. Humphreys, II, Auditorium. Then it was back to the Club for lunch, capped off by orange sorbet over fresh black berries and a JJSS business meeting. The dessert was delicious and the meeting was remarkable for two related committee actions. Chairman Larry Jordan reported that his Membership Committee was proposing our first Honorary Member and John Schullinger reported a Steering Committee proposal to change the By-Laws to expand eligibility for Honorary Membership to non-surgeon physicians as well as surgeons. The latter will require a quorum vote next year.

John Schullinger and his program committee gathered a top-notch panel of (mostly New York based) JJSS members, who have contributed mightily to the catheter and computerized-imaging based “Renaissance in Vascular Surgery.” Jack Jacobson moderated the symposium with a light hand, apropos the presenters' notable expertise. Its on-time ending allowed for the usual scurry to arrive at a lovely reception and dinner at the New York Athletic Club. All of this was without any registration fee or dues, thanks to Interim

Department Chairman, Craig Smith, and splendidly organized by Ms. Trisha Hargaden.



Scutigera coleoptrata.

This “Centipedean” issue of the Newsletter features Columbia University Medical Center (CUMC) and its antecedent's role in the evolution of the treatment of vascular diseases and in its ongoing catheter and image based renaissance. “QuantiaMD” has posted the entire “Renaissance in Vascular Surgery” symposium on the web providing license for its deconstruction and integration with the Day's other educational activities. This realignment reveals the timeliness and broad focus that characterized the 2008 John Jones Surgical Day. As shown in the Table, the program encompassed nearly all of Surgery's important, contemporary, patient-centric issues, rendering your absence even more lamentable.

Please set aside Friday, May 8 on your 2009 calendar and you should probably bring your rain coat.

Jim Chandler

Burning Issues of the Day

Issue	Forum	Participants
Ensuring the future of our discipline (page 10)	“Stump The Professor” show and tell	3rd year surgical clinical clerks, Jeffrey Cohen, Sherman Bull, Herb Mendell, Rich Nitzberg, and behind the scene, “Coaches” Warren Widmann and Mark Hardy
Technological innovations (page 11)		
<i>Catheter based endovascular procedures</i>	Symposium	Michael Marin, Tim Chuter, Roman Nowygrod
<i>Laparoscopic resection of solid organs</i>	Video presentations	James Lee, Andrew Gumbs, John Allendorf
<i>Natural Orifice Trans-Endoscopic Surgery “NOTES”</i>		Marc Bessler
Who should be (and is) doing what for whom? (page 14)	Video presentation Symposium	Marc Bessler George Todd
Understanding & mining large administrative data bases (page 15)	Symposium and video presentations	Jim McKinsey, Roman Nowygrod Nick Morrissey, James Lee, and, behind the scene, Jean Emond, Dennis Fowler, and William Inabnet
The molecular basis of disease (page 16)	Symposium	Dave Tilson

The Pre-renaissance Evolution of Vascular Surgery

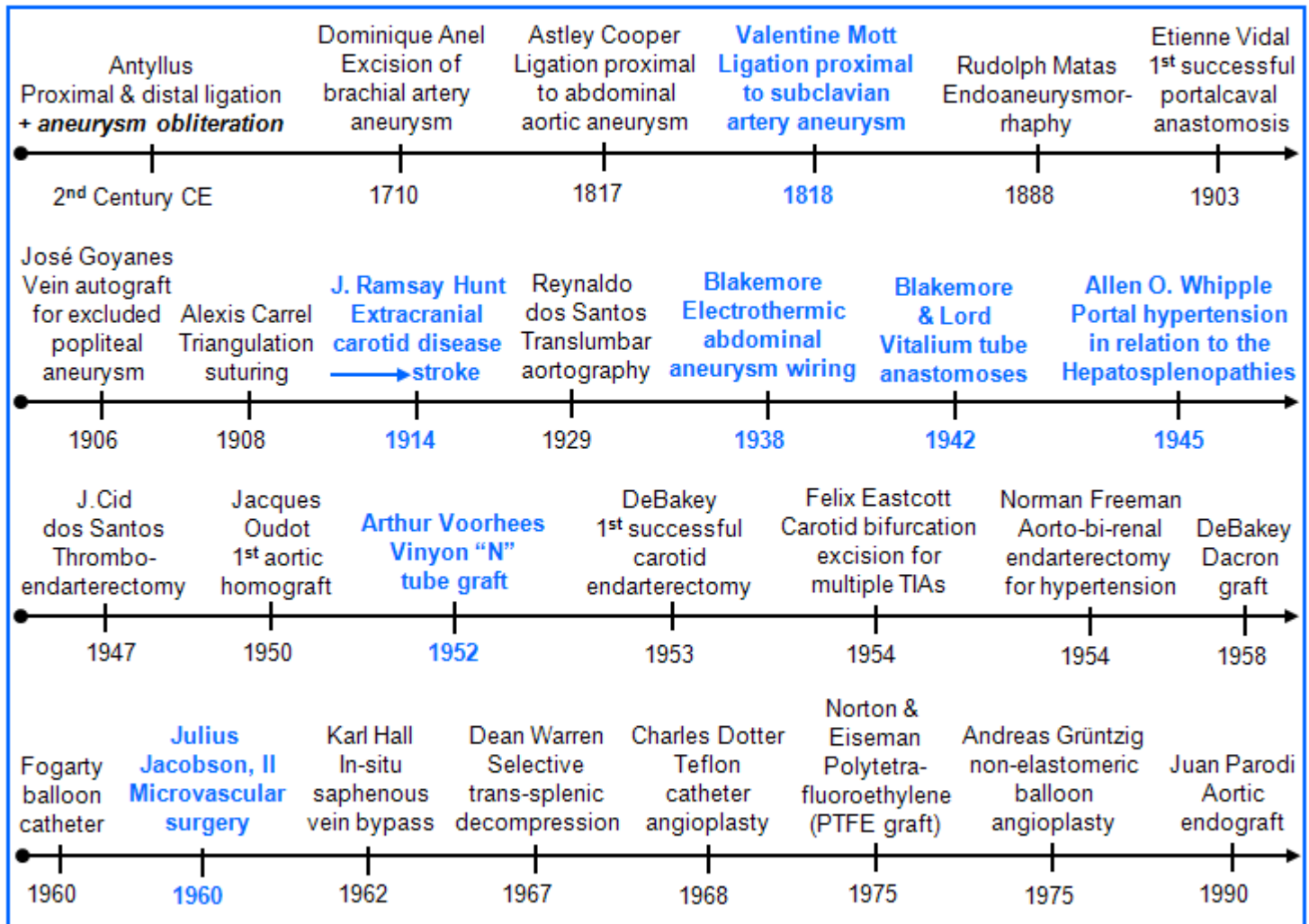
James G. Chandler and

Steven E. Novak, Head Archives and Special Collections. Augustus C. Long Health Sciences Library

This is an introductory background piece, not the star of the show. It is a necessarily selective review of events in the evolution of vascular surgery prior to the time when it was to become intimately intertwined with catheter-based, image-guided procedures. The ideas, missteps, and triumphs that comprise Columbia P&S faculty's participation are highlighted in blue in the following time line, which

provides a temporal framework for the story. Setting this out in the beginning frees the text to trace four principal evolutionary paths, focused sequentially on the treatment of Aneurysms, Extracranial Carotid Artery Disease, Portal Hypertension, and Peripheral Artery Injury and Disease without the clutter that would ensue from having to repeatedly relate events along one path to those in the others.

The Evolution of Vascular Surgery



Aneurysms


Antyllus, a Greek physician, who practiced in or near Rome in the second century, CE, was the first to differentiate true aneurysms from those arising from an arterial injury. His writings were transcribed in the 4th century by Oribasius (325-403), physician and friend of Julian, Rome's last polytheist Emperor, but the most accessible source for his thoughts on aneurysm management is Sir William Osler's¹ 1915 Radcliffe Infirmary lecture². Antyllus recognized natural aneurysms as being oblong and those arising from injuries, which were often iatrogenic, as being rounder, having a pal-

pable thrill, and comprising thicker tissue. He advocated operating for both types in the extremities and on the surface of the head, as long as they were away from the armpit, groin or neck. He cautioned against operating on these, or on exceptionally large aneurysms anywhere, fearing uncontrollable hemorrhage.

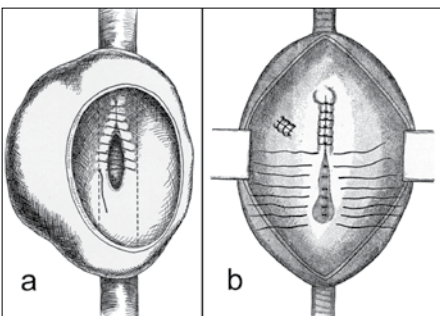
His operation for both types began with dissection of the parent artery above and below the aneurysm to permit proximal and distal ligation. He purposely tied these ligatures softly and advocated leaving the aneurysm in situ to prevent the "violent tension of the

¹Osler W. Arterio-venous aneurysm. *Lancet* 1915;1:949-55.

²Grant RL. "The William Osler Medal Essay": Antyllus and his medical works. *Bull Hist Med* 1960;34:154-74.



Iatrogenic brachial artery aneurysm which Antyllus would open and imbricate, and Aetius and Anell treated by proximal artery ligation alone, anticipating suppurative healing.³



a. Matas closure of saccular aneurysm with preservation of parent artery lumen; b. within-sac sutured branch artery and in-process obliteration of fusiform aneurysm's parent artery lumen.⁴

In the case of saccular aneurysms, he was generally able to preserve the parent artery's patency, which was not possible with fusiform aneurysms. Matas' experience was with aneurysms of the larger peripheral arteries, but he speculated that the same approach could be used for the aorta. Some 60 years later, the simplicity of leaving a trimmed sac in situ and controlling its branch arteries from within was reprised again, after nearly a decade of struggling to avoid vena cava and iliac vein injuries. Working from within was to have yet another, and ultimate, reprisal in 1990.⁵

The names most deserving of intercalation between Antyllus and Matas are those of Aetius, living in sixth-century Amida on the Tigris River, Dominique Anel (1679-1730) practicing in Paris, and the Hunter brothers, who were Scots "living abroad" in London. Aetius and Anel both advocated simple proximal ligation for crook-of-the-elbow aneurysms, and William (1718-83), the elder of the two Hunters, described two cases of aortic aneurysm complicated by an aorto-caval fistula. We have chosen instead to focus on Valentine Mott, Professor of Surgery at P&S, from 1813 (at age 28) until 1826.

arterial pneuma" from dislodging them, as might happen were the aneurysm to have been extirpated. In the case of round aneurysms, he added ligatures to encompass the tissue beneath the aneurysm before incising its presenting wall. He then evacuated the thrombus and obliterated its lumen by imbrication, presaging Rudolph Matas of New Orleans by nearly 18 centuries.

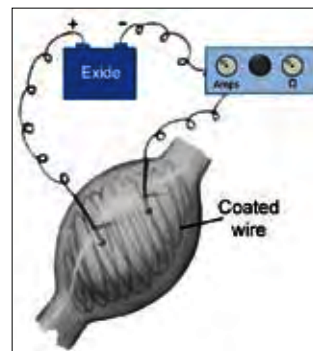
Matas⁴ begins his 1903, seminal, aneurysmorrhaphy paper by crediting Antyllus for "the old operation," which he was now reprising as being safer and more efficacious than dissecting around the aneurysm to excise it. Matas used elastic loops to control the parent artery until he was able to secure its orifices and those of branch arteries from within the lumen. In

the case of saccular aneurysms, he was generally able to preserve the parent artery's patency, which was not possible with fusiform aneurysms. Matas' experience was with aneurysms of the larger peripheral arteries, but he speculated that the same approach could be used for the aorta. Some 60 years later, the simplicity of leaving a trimmed sac in situ and controlling its branch arteries from within was reprised again, after nearly a decade of struggling to avoid vena cava and iliac vein injuries. Working from within was to have yet another, and ultimate, reprisal in 1990.⁵

Mott had studied with Astley Cooper; one of John Hunter's (1728-93) most distinguished pupils, and had remained at Guy's hospital for two years, seeing firsthand how aneurysms responded to proximal parent artery ligation.

Mott⁶ treated a trauma-induced aneurysm of the right subclavian artery, "as large as a hen's egg," in a 21 year old woman, who was referred to him in 1831. This was at least his second attempt to cure an aneurysm of the right subclavian artery by proximal ligation. He operated through a triangular flap incision at the intersection of the posterior edge sternocleidomastoid and medial portion of the clavicle. This provided exposure to approach the origin of the subclavian through the interval between the scalene muscles, while staying well away from the false aneurysm itself. He encircled the artery using a curved ligature carrier and had no difficulty tying in the depth of the wound. Pulsations in the aneurysm and in the arm ceased immediately. Mott's meticulous daily notes tell of pain in her neck and arm but make no mention of difficulty in breathing or hoarseness. On the 8th day after her operation, dark blood seeped from the wound, which was to recur almost daily and to be joined by persistent fever, until 6:00 am, on the 16th day, when "a profuse gush took place, accompanied with a jet, and whizzing noise." No more hemorrhage was to occur. She lived until the afternoon of the next day when she "died without a struggle."

In the early part of the 19th century a surgical feat was judged to be a success if the intended procedure was actually accomplished. Short-term, bad outcomes were anticipated by both families and colleagues and did not adversely affect a bold surgeon's reputation. By the time of his death in 1865, Mott was described as a "Patriarch of American Surgery." His *Lancet* obituary credited him with a passel of arterial ligations, tying the carotid 46 times and the subclavian 7 times - "every one of them successfully," the iliac 7 times, and the femoral 52 times.⁷ It states further that he had performed 165 cystolithotomies and nearly 1000 amputations, including at least one through the hip joint.



Aneurysm wiring and resistance heating⁸

Treating aneurysms of large arteries by parent vessel ligation continued to have poor results, with erosion into the vessel and life-ending hemorrhage. This was particularly true for the aorta, even when the constriction was controlled and made with a broad flat band.⁸ Wrapping was similarly ineffective in staving off hemorrhage. In 1935, Arthur Blakemore and physiologist Barry King decided to revisit a technique of packing an aneurysm with continuous coils of wire and heating the wire with an electric current to cause thrombosis among the coils. The concept was more or less to mimic the effect of rebar in concrete and was often combined with external constriction. By 1952 they had wired, or wired and banded, 32 abdominal aneurysms. Three ruptured in the immediate post operative period, six more ruptured after 1 to 18 months, and at least one patient lived

³Figure adapted from Suy RME. *Arterial Aneurysms: A Historical Review*. DEMOL Printing, Sint-Genesius-Rode, Belgium; 2004.

⁴Matas R. An operation for the radical cure of aneurism based upon arteriorrhaphy. *Ann Surg* 1903;37:161-96.

⁵The EVAR revolution: creating history - an interview with Juan Carlos Parodi. *Endovascular Today* 2004;Nov-Dec:51-4 (http://www.evtoday.com/PDFarticles/1104/F4_Parodi.html).

⁶Mott V. Case of aneurysm of the right subclavian artery, in which the vessel was tied within the scaleni muscles. *Am J Med Sci* 1833;12:354-9.

⁷Obituary of Valentine Mott, MD, LLD. *Lancet* 1865;85:553.

⁸Jacobson JH II, McAllister FF. A method for the controlled occlusion of larger blood vessels. *Ann Surg* 1957;145:334-43.

for two years.⁹ Although no report exists, it is hard to imagine that resection and replacement with a Vitalium tube was not tried at least once. It would have been an early failure, as rigid materials were incompatible with the “violent tension of the [aorta’s] pneuma.”

Resection and replacement with a tube approaching the aorta’s plasticity had to be the answer. The French obliged with homografts removed under sterile conditions, and preserved at 4°C in saline, to which antibiotics and human serum had been added. Jacques Oudot used the first one to replace an aortic bifurcation at the Salpêtrière hospital in 1950. Within a year, fellow Parisian, Charles Dubost used another to do an aorto-iliac reconstruction following resection of a large infra-renal aneurysm at La Semaine des hôpitaux de Paris.

In 1950, Arthur B. Voorhees, Jr. had already been musing for several years about fine-mesh fabric tubes that might become totally endothelialized if the fabric had the proper porosity. He had done a little experimenting with hand-sewn tubes of nylon parachute cloth and handkerchief silk and found them wanting. Upon his return to the Presbyterian Hospital after a two-year stint in the Fort Sam Houston Research Unit, he came upon Vinyon “N,” which had been designed for use as a sail cloth but was too inert to be dyed and consequently was a commercial flop. The weave was coarse but tight and the flat plastic fibers would fray when cut, requiring that the sewing edges always had to be folded over like a dress seam. This was, in a way, appropriate, as he was fabricating the tubes on his wife’s sewing machine. By 1952, Voorhees and his colleagues¹⁰ were able to report on Vinyon “N” tubular aortic grafts in 15 dogs, with patency out to 153 days. It looked like his vision was to become a reality. There was no giant-cell foreign body reaction. Fibroblasts had grown through the interstices of the cloth and the internal surface was completely covered by a thin pseudo-intima.

Two years later, Blakemore and Voorhees¹¹ published their clinical experience with Vinyon “N” grafts as replacements for 17 infra-renal aortic aneurysms and one popliteal aneurysm. Voorhees had succeeded in making bifurcated grafts, which were used in 6 cases. Tough lessons were learned about clamp placement and declamping events, and only 9 of the 17 aortic patients left the hospital. The longest follow up was just 10 months, but proof of concept and a new era of vascular surgery had been established. The full richness of this story can be found in two Presidential addresses by JSS member, Robert B. Smith III,¹² Art’s protégé, colleague, and friend and Voorhees’¹³ own recounting.

Blakemore and Voorhees’ publication was also timely, as reports of aneurismal degeneration in homografts were accumulating and about to replace enthusiasm with disillusionment. American vascular surgeons, including Art’s colleagues at P&S, were particularly open to exploring a variety of graft materials.¹⁴ Dacron™ (polyester) emerged as the favorite for its ease of fabrication into tubes and bifurcated grafts and their anatomical adaptability, which were rapidly brought to the fore by DeBakey and colleagues¹⁵ prodigious clinical activity.



Arthur B. Voorhees Jr. and Robert B. Smith, III, at the Homestead in (not so) Hot Springs, VA, in December 1978.

Extracranial Carotid Artery Disease

Genesis:

The rationale for studying and treating extracranial carotid artery disease began with P&S Associate Professor of Nervous Diseases, J. Ramsay Hunt’s¹⁶ presentation to the American Neurological Association in June of 1913. Traditional teaching linked stroke and pathological softening of brain tissue to thrombosis or localized rupture of the intracranial artery branches distal to the circle of Willis. The concept assumed that the circle’s communicating arteries would compensate for a more proximally sited occlusion, an idea that was reinforced by generally salubrious results that followed ligation of the carotid artery in penetrating neck wounds. The severed artery was nearly always the anatomically vulnerable common carotid, and the victims, or combatants, were typically young men, virtually assuring that distal external and internal cross communications would protect the ipsilateral brain tissue, provided that bleeding was promptly stanching. The primacy of intracranial lesions also endured because the vessels in the neck were customarily not disturbed in necropsies, out of deference to the wishes of embalming morticians.

Dr. Hunt linked stroke to extracranial carotid thrombosis, by analogizing distal limb ischemia associated with iliac artery obstruction as the pressure head becomes inadequate to provide sufficient flow in the distal smaller vessels and took note of the potential for emboli from a proximal site to have a similar effect. He supported his hypothesis by citing cases of hemiplegia that were associated with diminished contralateral carotid pulses high in the neck. Hunt also reported a patient with cervical carotid thrombosis consequent to trauma, who developed pallor of the optic papilla on the injured side, which coincided with the onset of a contralateral hemiplegia. He concluded by admonishing clinicians and pathologists to think of lesions in the extracranial cervical arteries and actively seek evidence of their presence.

⁹Blakemore AH. Progressive constrictive occlusion of the aorta with wiring and electrothermic coagulation for the treatment of arteriosclerotic aneurysms of the abdominal aorta. *Ann Surg* 1953;137: 760–74.

¹⁰Voorhees AB Jr, Alfred Jaretski A III, Blakemore AH. The use of tubes constructed from Vinyon “N” cloth in bridging arterial defects: a preliminary report. *Ann Surg* 1952;135:332–6.

¹¹Blakemore AH, Voorhees AB Jr. The use of tubes constructed from Vinyon “N” cloth in bridging arterial defects—experimental and clinical. *Ann Surg* 1954;140:324–33.

¹²Smith RB III. Presidential address: the foundations of modern aortic surgery. *J Vasc Surg* 1998;27:7–15. Smith RB III. Arthur B. Voorhees, Jr.: pioneer vascular surgeon. *J Vasc Surg* 1993;18:341–8.

¹³Voorhees AB Jr. The development of arterial prostheses: a personal view. *Arch Surg* 1985;120:289–95.

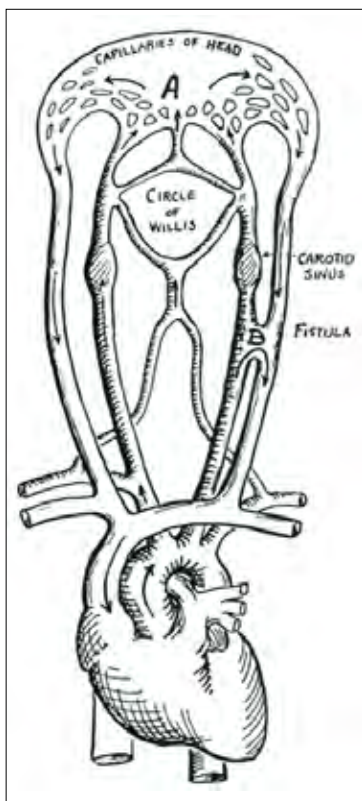
¹⁴Deterling RA Jr, Bhonslay SB. An evaluation of synthetic materials and fabrics suitable for blood vessel replacement. *Surgery* 1955;38:71–91.

¹⁵DeBakey ME, Cooley DA, Crawford ES, Morris CG Jr. Clinical application of a new flexible knitted Dacron arterial substitute. *Am Surg* 1958;24:862–9.

¹⁶Hunt JR. The role of the carotid arteries in the causation of vascular lesions in the brain, with remarks on certain special features of the symptomatology. *Am J Med Sci* 1914;147:704–13.

Numbers:

Hunt proved to be a prophet in the wilderness in the absence of diagnostics beyond physical examination, and nearly 40 years of meandering were the consequence. At P&S, investigation of the extracranial carotid circulation was spearheaded by Blakemore, Humphreys, and King's¹⁷ exploration of experimental carotid-jugular fistulas and the differing pressures that a unilateral fistula imposed on the two carotid sinuses. Their interest was stimulated by Emile Holman¹⁸ having established that the primary effect of an arterial venous fistula was to diminish peripheral vascular resistance in proportion to its size and proximity to the heart. The decreased resistance consistently lowered arterial pressure, despite compensatory increments in vascular volume and cardiac output. This had led a few surgeons to construct an A-V fistula distal to an aortic aneurysm as a putative means of delaying or avoiding rupture, which Blakemore and his colleagues viewed with suspicion.



Diagrammatic schema, to show the relationship of a side-to-side carotid jugular fistula to the systemic circulation and arterial anastomoses in the head.¹⁷

being that cerebral capillary flow would be increased by systemic vasoconstriction and pressurizing the venous sinuses. The second involved a data-free assumption that more flow would improve brain tissue oxygenation, and the third postulated that better oxygenation might result in improved mentation in mentally defective children. The anastomosis was preferentially performed between the right external carotid and the internal jugular vein, doubly ligating and transecting the latter immediately below the fistula. This procedure

Their subsequent studies of chronic A-V fistulas showed that dilatation and thinning of the aortic wall regularly occurred proximal to an A-V fistula, suggesting that its therapeutic use for aneurysms was ill conceived. Positioning of a fistula in the carotid-jugular axis was especially counterproductive because the carotid sinus immediately cranial to the fistula perceived the lower pressure in the capillary-excluding short circuit and stimulated systemic vasoconstriction and hypertension, unless it was denervated.

Years later, these observations about the uniqueness of an arterio-venous fistula in the carotid-jugular axis were interpreted as offering a means of augmenting cerebral blood flow, particularly, if the venous return from the fistula was directed back through the intracranial venous sinuses. This concept involved three giant leaps of faith: the first

was assessed, under the aegis of P&S and the State of New York's Department of Mental Hygiene, in 25 low-intelligence-quotient children, without observing any appreciable improvement at two years, and engendering persistent, unilateral exophthalmos in nine patients.¹⁹ Interestingly, the idea of increased cognition consequent to augmented cerebral blood flow has proven to be remarkably durable despite equally persistent data confliction.²⁰

True carotid revascularization began with a single case in 1951, 37 years after Hunt's publication.²¹ Buenos Aires neurosurgeon, Raul Carrea, excised a severely stenotic origin of the internal carotid that had been identified by direct-carotid-stick arteriography, restoring continuity with an end-to-end anastomosis. The patient had presented with an established hemiparesis and expressive aphasia, and both largely resolved over the next two months. Eastcott, Pickering, and Rob famously reported doing a similar resection in May 1954 for recurrent transient ischemic attacks. "Famously" because it was just 13 days after Dr. Roger Bannister ran his 4-minute mile, and related, because Bannister was about to start as a registrar on Pickering's medical service.²¹ Famous as well because it jump-started carotid endarterectomy, obscuring DeBakey's later report of his 1953, seminal and successful carotid endarterectomy with documented patency at four years.

Ramsay Hunt was more on target than he or any of his contemporaries could ever have imagined. Modern angiography and duplex Doppler studies were to reveal that extracranial atherosclerosis accounts for 80% of all stenotic carotid lesions in Caucasians, albeit, with intracranial stenoses being proportionally more common in Asians and, to a lesser extent, in Blacks.²² The societal cost, degree of disability, and prevalence of stroke, coupled with the introduction of Seldinger-technique angiography and sonographic imaging, became tremendous drivers for carotid endarterectomy but did not rescue it from the wilderness beyond the perimeter of evidence based medicine.

It soon became apparent that operating on an acute stroke hazarded serious worsening, and that operating for transient ischemic attacks was more risky than operating for asymptomatic lesions, which resulted in a large number of carotid endarterectomies falling into the last category. Two prospective, randomized, controlled studies in the 1970s, comparing carotid endarterectomy vs. medical therapy for preventing strokes, had less than definitive results. State-wide surveys and studies based on hospital discharge data showed order-of-magnitude greater combined postoperative stroke and death rates than those reported from centers of excellence. The juggernaut, however, was undeterred. The number of carotid endarterectomies performed in US hospitals peaked at 107,000 in 1985, a year in which a large, international, randomized trial of extracranial-intracranial branch bypasses failed to confirm their effectiveness.²³ The lesion locations were obviously different, the vessels involved were much smaller in scale, and had to pass over the edges of a drill hole in bone, but the question of carotid revascularization's efficacy rapidly spread right down to the collar bones.

Deuteronomy:

Neurosurgeons criticized the "EC-IC" study as being unrepresentative

¹⁷Blakemore AH, Humphreys GH, King BG. Experimental studies in carotid-jugular anastomosis with special reference to the role of the carotid sinus. *Ann Surg* 1937;105:74-92.

¹⁸Holman E. Arteriovenous aneurysm: clinical evidence correlating size of fistula with changes in the heart and proximal vessels. *Ann Surg* 1924;80:801-16.

¹⁹Jervis GA, McAllister FF, Hogg BM, Deterling RA Jr. Revascularization of the brain in mental defectives. *Neurology* 1953;3:871-8.

²⁰Berman L, Pietrzak RH, Mayes L. Neurocognitive changes after carotid revascularization: a review of the current literature. *J Psychosom Res.* 2007;63:599-612.

²¹Rosenthal D. Presidential address: Thirteen days in May. *J Vasc Surg* 2002;36:430-6.

²²Li H, Wong KS. Racial distribution of intracranial and extracranial atherosclerosis. *J Clin Neurosci* 2003;10:30-4.

²³EC/IC Bypass Study Group. Failure of Extracranial-intracranial arterial bypass to reduce the risk of ischemic stroke: results of a randomized trial. *N Engl J Med* 1985;313:1191-1200.

sentative because many more bypasses were being performed contemporaneously outside of the study than within it at most of the participating institutions but could not fault the study's data. Vascular surgeons struggled to define cervical carotid plaque characteristics and subsets of patients that would clearly benefit, opening the door for the Rand Corporation to step in and retrospectively classify 13,000 Medicare-funded carotid endarterectomies as appropriate, equivocal, or inappropriate, in approximately equal proportions.²⁴

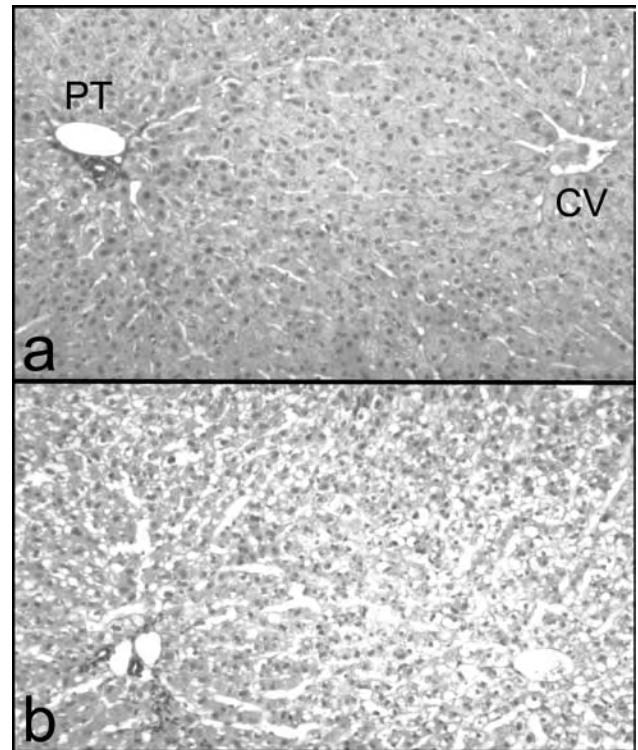
Codification was clearly needed; yet, several years were required to develop standards for center and patient eligibility, and agreement on stenosis measurement. The latter involved measuring maximum stenosis, divided by normal internal carotid diameters in two planes, and using the higher percentage value to stratify patients into moderate 50-69% and high grade 70-99% stenosis groups. Symptomatic patients who had a recent transient ischemic attack or a non-disabling stroke were the first to be studied, beginning in 1988. In just three years, the 70-99% stenosis carotid endarterectomies had caused a significant, absolute two-year cumulative ipsilateral stroke risk reduction of 17% compared to optimal medical therapy among 659 patients.²⁵ This was sufficiently definitive to stop enrolling high-grade-stenosis patients. The moderate stenosis part of the study went on to add a less than 50% stenosis group and to randomize more than 2,000 symptomatic patients. A significant absolute stroke risk reduction of 7% over 5 years was achieved in the 50-69% stenosis group.²⁶ Operating on less than 50% stenosis patients was shown to offer no advantage over best medical therapy.

Two subsequent randomized trials confirmed the comparative benefit of endarterectomy in high-grade stenosis patients. As might be expected, the advantages of operating over best medical therapy in asymptomatic patients with greater than 50% stenosis have, on balance, been less uniformly favorable. The role of the new player in the mix, endovascular carotid arterial stenting combined with protection against larger particle embolization, is still evolving but is being pursued in a manner that should allow evidence-based decision making for all three options within the next five years.²⁷ EC-IC bypass has also emerged from retrenchment, shepherded by stricter patient selection and assurance that preoperative donor-artery flow is adequate and remains so through the completed bypass.²⁸

Portal Hypertension in Relation to the Hepatosplenopathies²⁹

Nicolai Validimirovich Eck's 1877 portalcaval anastomoses in eight dogs proved to be prototypical of the subsequent struggle to understand the complex consequences of altering the liver's dual input circulatory system. Seven of the eight dogs died within a week, and the sole survivor wandered away after two and a half months when a diener failed to secure its cage. As a consequence, "meat intoxication" was not noted until shunted dogs were studied in Pavlov's laboratories in the 1890's. His group made the prescient observation that dogs would not become encephalopathic, if the flow from the last entering portal tributary, which drains the pancreas and duodenum, was not included in the diversion into the vena cava.²⁹

Animals vary in their vulnerability to shunt-related enceph-



a. Normal rabbit liver, PT= Portal Triad containing interlobular artery, portal vein and bile duct, CV= Central vein; **b.** Comparable area 14 days after complete portal diversion, note central necrosis and lobule shrinkage, as evidenced by less separation between PT and CV.

alopathy: rats never become confused, dogs are intermediate, and rabbits are extraordinarily susceptible. The more resistant species compensate for the main channel loss by expanding pre-existing hepatopetal venous collaterals. The rabbit cannot do this and regularly develops lassitude and ataxia associated with central lobular necrosis, going on to die of liver failure in four to six weeks, unless a portion of the portal flow was preserved.

The first successful portalcaval shunt in humans was done by dividing the portal vein, ligating the stump in the liver hilum, and anastomosing the proximal end to the side of the vena cava by Etienne Vidal in 1903 [often referenced as Vidal, M (for Monsieur)]. His patient had had both ascites and hematemesis. The patient did not bleed again but his ascites reappeared in six weeks. His shunt undoubtedly remained patent because he became encephalopathic whenever he ingested more than a very limited amount of protein during the three and half months in which he survived.²⁹ Vidal's patient had alcoholic liver disease with both splanchnic and sinusoidal hypertension. Had Vidal chosen to make a side-to-side anastomosis and not ligate the portal vein's hepatic limb, it would have served to decompress the sinusoids and the peri-sinusoidal lymphatic spaces of Disse. This would have avoided the reaccumulation of ascites but not altered his patient's proclivity to become encephalopathic.³⁰

The observations of Pavlov's group did not go unnoticed. Partial shunting of the superior mesenteric flow was used successfully

²⁴Winslow CM, Solomon DH, Chassin MR, et al. The appropriateness of carotid endarterectomy. *N Engl J Med* 1988;318:721-7.

²⁵North American Symptomatic Carotid Endarterectomy Trial Collaborators. Beneficial effect of carotid endarterectomy in symptomatic patients with high-grade carotid stenosis. *N Engl J Med* 1991;325:445-53.

²⁶Barnett HJ, Taylor DW, Eliasziw M, et al. Benefit of carotid endarterectomy in patients with symptomatic moderate or severe stenosis. *N Engl J Med* 1998;339:1415-25.

²⁷Lin PH, Barshes NR, Annambhotla S, Huynh TT. Prospective randomized trials of carotid artery stenting versus carotid endarterectomy: an appraisal of the current literature. *Vasc Endovascular Surg* 2008;42:5-11.

²⁸Wanebo JE, Amin-Hanjani S, Boyd C, et al. Assessing success after cerebral revascularization for ischemia. *Skull Base* 2005;15:215-27.

²⁹Chandler JG. The history of the surgical treatment of portal hypertension. *Arch Surg* 1993;128:925-40.

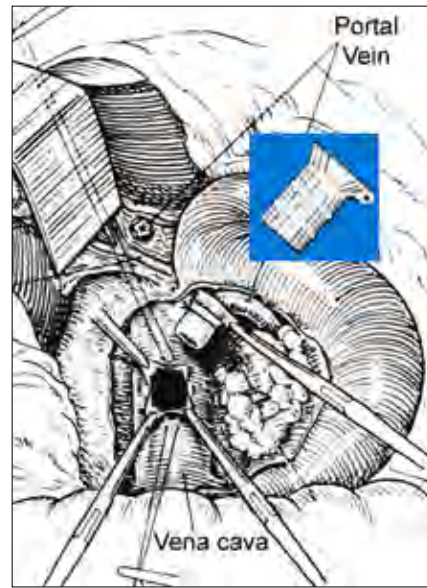
³⁰Orloff MJ, Chandler JG, Charters AC III, et al. Comparison of end to side and side to side portalcaval shunts in dogs and human subjects with cirrhosis with portal hypertension. *Am J Surg* 1974;128:105-201.

by two groups and others chose to limit flow diversion by making the shunt less central and thus necessarily smaller. In the days before swedged on needles, the hole made by the passage of the needle's eye and its loop of suture was not completely occupied by the single strand that was to remain, and suture line bleeding was the rule. Prolonged compression to achieve hemostasis was hard on these small anastomoses, and most seemed to thrombose almost as the abdomen was being closed. An era of discouragement ensued, and publications on the subject disappeared coincident with America's entrance into World War I.

A single scholarly review brought the surgical treatment of portal hypertension back into focus. The venue was to have been the 1945 meeting of the American Surgical Association, which was not held for another war's security reasons. The scholar was Allen O. Whipple,³¹ who was in his last year as Chairman of P&S's department of surgery, and the title of his paper, in slightly abbreviated form, heads this section. He described the interactions between portal flow, normally 75% of inflow, and hepatic arterial flow, which occur as the two emerge into the periphery of the sinusoids, adjacent to the interlobular portal triads. Hepatic arterial flow increases proportionally when cirrhosis impedes outflow from the central lobular vein through scarring and regenerative nodularity. He quoted cirrhotic liver perfusion studies, wherein more than 85% of fluid infused into the portal vein is lost through collaterals, resulting in nearly exclusive arterial sinusoidal perfusion. Hepatofugal collateral veins that are not well supported and near epithelial surfaces are likely to bleed when the static pressure within them reaches 25-30 mm/Hg. Ascites, in this situation, is a marker of a sinusoidal overflow condition, wherein sinusoidal plasma leaks into the spaces of Disse, causing excess lymph to exude through Glisson's capsule and its extension along the extra-hepatic bile ducts.

Whipple clearly differentiated pure pre-sinusoidal portal hypertension, caused by Schistosomiasis in countries where the parasite's larvae are encountered by swimming in snail infested waters, but more commonly associated with varying degrees of portal vein thrombosis in the US. Typically, hepatopetal collaterals are present, but the dominant features are huge, thin-walled, tortuous hepatofugal veins, hypersplenism, and ascites, which is splanchnic in origin, and weeps through the visceral peritoneum from mesenteric lymphatics. These patients can survive multiple esophago-gastric hemorrhages, since their liver function is essentially normal.³² Splenectomy is curative if the thrombosis is limited to the splenic vein, simultaneously decompressing the typically gastric varices and eliminating hypersplenism's "triple -penias." More extensive thrombosis limits shunting options, and sometimes there are none, in which case esophago-gastric devascularization or even resection might be warranted.³³

Whipple went on to describe Blakemore and Lord's³⁴ use of a



Vitalium cuff, non-suture, end-to-side portacaval shunt, adapted from Whipple.³¹

Vitalium cuff (VC) to construct portosystemic shunts. The unique aspect of the various versions of their fastening device was that the portal or splenic vein passed through the VC's lumen and then was everted back over the outside of the Vitalium tube to present an endothelial surface for anastomosis to either the inferior vena cava or renal vein. These non-suture anastomoses were quite successful in the short term but were subject to gradual occlusion.

Using major post shunt re-bleeding as a surrogate, 12 of 25 VC anastomoses thrombosed, compared to only a 10% incidence among 111 sutured shunts.³⁵

By 1970, Voorhees, Price, and Britton³⁶ were able to report a remarkable 26-year series of 748, primarily end-to-side shunts, beginning with Blakemore and Lord's cases. Robert Linton,³⁷ at the Massachusetts General Hospital, published a similar review of principally splenorenal shunts, making for some lively New York-Boston interchanges about patency durability and proneness to encephalopathy. Jim Sarfeh³⁸ and Dean Warren³⁹ subsequently curtailed this debate by revisiting diameter limited and remote, isolated shunting.

Whipple's paper actually engendered a reawakening of interest in a broad spectrum of therapies, including operations such as transposing the spleen into the chest or the abdominal wall to provide a trans-splenic route for variceal runoff. Most of these need to be passed over because they would be ectopic in a vascular surgery review, although the aforementioned example might have influenced Warren's shunt design. Two particulars, however, deserve both mention and referencing: the first because it arose in Whipple's successor's Department and the second because it evolved into a major factor in tamping down portosystemic shunting. Sengstaken and Blakemore's⁴⁰ 1950 report of their uptown advocacy of balloon tamponade from within was matched by a contemporaneous, midtown interest in trans-cervical mediastinal packing to arrest acute variceal bleeding.⁴¹ The former easily bested the latter in terms of acceptance and clinical utility. But, both were destined to be banished by a reawakening of interest in Crawford and Frencner's⁴² 1939, modest reporting of their three-year success in permanently obliterating a

³¹Whipple AO. The problem of portal hypertension in relation to the hepatosplenopathies. *Ann Surg* 1945;122: 449-75.

³²Voorhees AB Jr, Harris RC, Britton RC, Price JB, Santulli TV. Portal hypertension in children: 98 cases. *Surgery* 1965;58:540-9.

³³Habif DV. Treatment of esophageal varices by partial esophagogastric resection and interposed jejunal segment. *Surgery* 1959;46:212-37.

³⁴Blakemore AH, Lord JW Jr. The technic of using vitalium tubes in establishing portacaval shunts for portal hypertension. *Ann Surg* 1945;122: 476-89.

³⁵Blakemore AH. Portacaval shunting for portal hypertension. *Surg Gynecol Obstet* 1952;94:443-54.

³⁶Voorhees AB, Price JB, Britton RC. Portosystemic shunting procedures for portal hypertension: Twenty-six year experience in adults with cirrhosis of the liver. *Am J Surg* 1970;119:501-5.

³⁷Linton RR. Portal hypertension as I see it in 1973: the treatment of bleeding esophageal varices secondary to portal cirrhosis of the liver. *Major Probl Clin Surg* 1974;14:196-232.

³⁸Sarfeh IJ, Rypins EB, Conroy RM, Mason GR. Portacaval H-graft: relationships of shunt diameter, portal flow patterns and encephalopathy. *Ann Surg* 1983;197:422-26.

³⁹Warren WD, Zeppa R, Foman JJ. Selective trans-splenic decompression of gastroesophageal varices by distal splenorenal shunt. *Ann Surg* 1967;166:437-55.

⁴⁰Sengstaken RW, Blakemore AH. Balloon tamponade for the control of hemorrhage from esophageal varices. *Ann Surg* 1950;131:781-9.

⁴¹Garlock JH, Som ML. Further observations on packing of mediastinum for esophageal varices. *J Thorac Surg* 1950;19:572-88.

⁴²Crafoord C, Frencner P. New surgical treatment of various veins of the oesophagus. *Acta Otolaryngol (Stockh)* 1939;27:422-9.

16 year old girl's esophageal varices by repeated, endoscopic, intravariceal injections of quinine.

Now, few surgeons have experience with any type of porto-systemic shunt. Trans-jugular intravenous portalcaval stenting (TIPS) has stolen the scene with covered stents, both for long-term decompression in patients with good hepatic reserve and as a bridge to transplantation.⁴³ Neither TIPS, nor liver transplantation, are applicable therapies for patients with portal vein thrombosis unassociated with cirrhosis. Acutely, long-term anticoagulation is effective. In selected mature-occlusion cases, it is possible to carve out a channel that will persist, but mesocaval shunting and esophago-gastric devascularization remain the surgical mainstays, when endoscopic variceal obliteration fails.

Peripheral Artery Injury and Disease

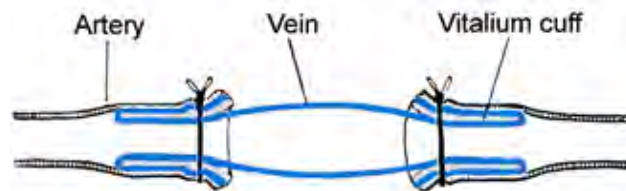
Alexis Carrel, who had trained in surgery in Lyon, France, joined the Rockefeller Institute for Medical Research on York Avenue at East 66th Street in 1906. José Goyanes⁴⁴ of Madrid had just reported the first use of a venous allograft to bypass a human artery, in his case, for the purpose of excluding a popliteal aneurysm. Whether Carrel was aware of this or not, he began studying the function and durability of fresh arterial and venous homografts as replacements for excised segments of the carotids and abdominal aorta in dogs. He noted wall thickening of veins in response to arterial pressure, and that they did not become aneurismal, but were more prone to later occlusion than arterial transplants. This led Carrel⁴⁵ to explore cold preservation of arterial grafts, which he was able to do successfully for periods up to 10 days. In this, as well as in all of his experimental procedures, he was meticulous in maintaining asepsis, as infection would guarantee failure. The paper includes a page-1664, tantalizing "single-shoe-drop" statement: "I found also that it is possible to use peritoneum as a substitute for the arterial wall."

In 1908, Presbyterian Hospital surgeon, Adrian V. S. Lambert prevailed upon Carrel to perform an artery-to-vein anastomosis between himself and his profoundly anemic infant daughter, who had been born with a dyscrasia that caused her to bleed repeatedly from her nose mouth and anus.⁴⁶ Carrel used his triangular traction technique, which avoided picking up the back wall in constructing an end-to-end anastomosis between the father's transected left radial artery and the infant's tiny popliteal vein. The circumstances were far short of those that Carrel regularly enjoyed in his laboratory: the father was lying on the dining room table and his baby daughter was strapped to an ironing board that also supported his forearm. The baby's color improved immediately upon removal of the clamps, and the transfusion of an unknown volume was somehow curative, perhaps by giving her time to outgrow an infantile dyscrasia. It was a fortuitous day for the Lamberts, as Karl Landsteiner was not to publish his work on ABO haplotypes until the following year.⁴⁷ However achieved, there is no doubt about the cure, as her surgeon was to have the pleasure of being an honored guest at her 21st birthday party.

At age 39, Carrel received the 1912 Nobel Prize in Medicine for

his triangulation anastomotic technique, making him, at the time, the youngest to have ever received any Nobel Prize. By then, P&S had been part of Columbia College for 11 years. The Presbyterian Hospital, located between Park and Madison Avenues and 70th and 71st Streets had been open for 30 years and had served as a principal teaching hospital for P&S students for a year. Sadly, despite his service to the Lambert family and Adrian Lambert becoming Presbyterian's Director of Surgery and President of its Medical Board, there is no record of any research collaboration between the Hospital's surgeons and Carrel's laboratory. Carrel remained active at the Institute until 1939, overlapping 18 years of Dr. Whipple's tenure as chairman and appeared, along with his collaborator, Charles Lindbergh, on the cover of Time Magazine the year before he retired. It is hard to imagine that his work could have gone unappreciated for its translational potential by New York's academic surgical community for 23 years.

This is not to say that Carrel's work was unknown to Presbyterian Hospital Surgeons. His anastomotic technique was used as the control procedure in Blakemore, Lord, and Stefko's⁴⁸ experiments in dogs, designed to test their double VC vein grafts in simulated battlefield wounds. They had a peculiar study design that assessed the sutured vein grafts at 14 days and the VC vein grafts at 7 days. Given this aberrance, the test grafts could be put in more rapidly and fared better, in terms of both patency and disruption, in contaminated wounds that were 6 and 24 hours old at the time of graft insertion. A composite of several publications documents anecdotal prolonged clinical patency of these anastomoses in two traumatically severed brachial arteries and in bridging gaps in the distal femoral and popliteal arteries.



Vitalium cuff vein graft, adapted from Blakemore, Lord, & Stefko.⁴⁸

In 1960, 16 years after Carrel's death, Julius H. Jacobson II⁴⁹ brought an eye/ear surgery microscope into the operating room to allow ordinary surgeons to see so well that they could not only emulate the Rockefeller scientist's legendary tiny-vessel anastomotic skills but actually surpass and extend them. Unlike industry's readiness to jump headlong into synthetic grafts, makers of medical instruments and operating microscopes were wary of microvascular surgery's potential. Neither of the two American microscope manufacturers would invest in making the double binocular scope needed to allow an operator and assistant to see equally well and coordinate their movements. Upper management acted like they were selling razor blades rather than specialized use razors, asking, "Will we ever sell 10,000 of these?" So, Jacobson appealed to the Zeiss Company, which, fortunately, had been transposed from Jena, in East Germany in 1945, to Oberkochen, in the West at the last possible moment be-

⁴³Colombato L. The role of transjugular intrahepatic portosystemic shunt (TIPS) in the management of portal hypertension. *J Clin Gastroenterol* 2007;41(Suppl 3):S344-51.

⁴⁴Goyanes J. Nuevos trabajos de cirugía vascular, substitucion plastica de las arterias por las venas ó arterioplasta venosa, aplicada, como nuevo metodo, al tratamiento de los aneurismas. *El Siglo Med* 1906;53:546-61.

⁴⁵Carrel A. Results of the transplantation of blood vesels, organs, and limbs. *JAMA* 1908;51:1662-7.

⁴⁶Friedman DM. The Immortalists: Charles Lindbergh, Dr. Alexis Carrrel and Their Daring Quest to Live Forever. HarperCollins, New York, 2007;pp 10-11.

⁴⁷http://nobelprize.org/nobel_prizes/medicine/laureates/1930/landsteiner-bio.html

⁴⁸Blakemore AH, Lord JW, Stefko P. Restoration of blood flow in damaged arteries: further studies of a non-suture method of blood vessel anastomosis. *Ann Surg* 1943;117:481-97.

⁴⁹Jacobson JH 2nd. Microsurgery. *Curr Probl Surg*. 1971; pp3-56.

fore the Curtain dropped. Zeiss agreed to give it a try and make a one-off “Diploscope” for him, with staged magnification from 5 to 40x and a 16-inch working clearance.

Soon thereafter, lamenting, newlywed husbands were lining up at Jack’s door to have their vas deferens reconstructed. Yet, he still had to convince his thought-leader surgical colleagues that no matter how skilled they were, they would be just that much better working on distal tibial vessels, seeing the field at 16x.⁵⁰ Although general surgeons, Ron Malt and Charlie McKhann,⁵¹ performed the first human arm reimplantation in 1962, plastic and orthopedic hand surgeons were quicker to realize the advantage of greater than 4x loop magnification, and, as a consequence, captured the field of limb and digit implantation. Zeiss went on to make the double binocular scope easier to use by motorizing its movements and sold their ten-thousandth unit several years ago. Digit reimplantation is holding its own: a recent meta-analysis examined more than 1,800 digit implants in nearly 1,300 patients.⁵² Dr. Jacobson’s original Diploscope appropriately resides in the Smithsonian National Museum of American History’s Lemelson Center for the Study of Invention and Innovation.

Aside from Vitalium, P&S surgeons tended to be followers rather than leaders in the application of foreign materials to reconstruct peripheral arteries. They recognized early on that synthetic grafts could not approach results achievable with the use of respectfully handled autogenous vein. DeBakey¹⁵ led the way with machine knitted, crimped Dacron tubes, reporting in 1958 that he had used the grafts in 270 peripheral artery reconstructions since 1957. Yet, 18 years later, Presbyterian Hospital surgeons had performed just 276 femoral popliteal bypasses of any type.⁵³ Only 75 involved Dacron grafts, which were always, second choice, for lack of a suitable vein. The results were fairly discouraging, as they were done for severe claudication as well as threatened limb loss: overall, the patency rate was 58% at 1 year and 40% at 5 years, dropping to 19% for Dacron grafts. Poor runoff was identified as the primary villain underlying vein graft failure, which, in the light of today’s knowledge and techniques, could retrospectively be interpreted as sometimes being an indicator of need for a more distally located plug-in site.

In 1971, William Gore and Ben Eiseman were having an après-ski dinner in Vail, CO with their wives, when Gore intentionally poured ketchup on his necktie. He casually wiped it off with his napkin, leaving no residue, and then produced a sheet of the same expanded polytetrafluoroethylene material, cupped it into his hand and showed that it retained water. The finale of this performance was to hold the same sheet in front of his mouth and extinguish a match by blowing through its tiny pores.⁵⁴ He was showing his newly patented PTFE to a prepared mind, as Eiseman⁵⁵ had already explored human umbilical vein as a potential arterial replacement more than a decade before Herbert Dardik made it into practicable graft with glutaraldehyde tan-

ning. Ben came down from the mountain and engaged himself and his minions in testing PTFE’s suitability for being a pump-oxygenator membrane, burn dressing, or substitute for bronchus, esophagus, bile duct, portal vein, aorta and peripheral arteries.

Its use as an arterial substitute in canine femoral and carotid arteries induced neo-intimal hyperplasia at both anastomoses, which limited their patency compared to what was easy to achieve in larger vessels, including portal veins in pigs. They used a PTFE tube as a replacement for a portal vein that had been removed en bloc with a pancreas cancer, which was the first use of PTFE in a human being.⁵⁶ The patient died three years later of coronary artery disease with a patent graft. PTFE’s use as a peripheral arterial substitute in humans eventually required an external lacing reinforcement and in some circumstances, a supporting continuous spiral stiffener. Still, the situation is much the same: PTFE, like crimped Dacron, does well from the axilla to the groin but cannot approach the results achievable with autogenous-vein crural artery bypasses.⁵⁷

Respectful handling of autogenous vein begins with ligating its tributaries without gathering the main vein’s adventitia, using cooled, heparinized saline mixed with a small amount of blood for perfusion and storing, and avoiding hydraulic over distention. Respectful handling also includes using the single tooth of fine toothed forceps to manipulate the veins cut edge without compressing its wall with the opposite blade and not allowing the intima to dry out when sewing. Using an un-harvested, in-situ vein minimizes handling and offers the advantage of better size correspondence for both anastomoses. Hall’s⁵⁸ original technique of excising valves through multiple incisions was tedious, and JSSS member, Jack Connolly’s⁵⁹ blunt-nosed vein stripper disruption worked well in his hands in over 300 cases, but not in those of others. Valvulotomes of various designs have made valve disruption simpler and less traumatic, and, in conjunction with intraoperative Doppler assessment, have obviated the need for a long incision and whole vein exposure.

This prelude to Vascular Surgery’s Renaissance should not overstep its bounds, but its role in providing perspective would be incomplete without revisiting the hostile reception accorded to Charles T. Dotter in the late 1960’s. His before and after pictures of superficial femoral artery catheter dilatations, that somehow remained patent, went against what we practiced and taught, constituting total disrespect for intima integrity. Dotter had gone to Cornell Medical School and trained in Radiology at the New York Hospital, making him now almost kin. The contemporary surgical perception of his work is epitomized by a 1964 request by a Portland, Oregon community surgeon for a left femoral angiogram with “Visualize but do not try to fix” written boldly across the form.⁶⁰ Dotter’s technique was better received in Europe and was the inspiration for Grüntzig’s development of a balloon that would expand to a predetermined size and shape, which was used first on a stenotic iliac artery in 1975.⁶¹

⁵⁰Liu EH. Where are they now? John Jones Surgical Society Newsletter 2007;10(Fall):14-15.

⁵¹Malt RA, McKhann C. Replantation of several arms. JAMA 1964;189:716-22.

⁵²Dec W. A meta-analysis of success rates for digit replantation. Tech Hand Up Extrem Surg. 2006;10:124-9.

⁵³Buda JA, Weber CJ, McAllister FF, Voorhees AB. Factors influencing patency of femoropopliteal artery bypass grafts. Am J Surg 1976;132:8-12.

⁵⁴Kelly GJ, Eiseman G. Development of a new vascular prosthetic: lessons learned. Arch Surg 1982;117:1367-70.

⁵⁵Yong NK, Eiseman B. The experimental use of heterologous umbilical vein grafts as aortic substitutes. Singapore Med J 1962;3:52-7.

⁵⁶Norton L, Eiseman B. Replacement of portal vein during pancreatectomy for carcinoma. Surgery 1975;77:280-4

⁵⁷Berglund, J, Björk M, Elfström on behalf of the SWEDVASC Femoro-popliteal Study Group. Long term results of above knee femoro-popliteal bypass depend on indication for surgery and graft-material. Eur J Vasc Endovasc Surg 2005;29:412-18.

⁵⁸Hall KV. The great saphenous vein used “in-situ” as an arterial shunt after extirpation of the vein valves: a preliminary report. Surgery 1962;51:492-5.

⁵⁹Connolly JE, Stemmer EA. The nonreversed saphenous vein bypass for femoral-popliteal occlusive disease. Surgery 1970;68:602-9.

⁶⁰Rosch J, Abrams HL, Cook W. Memorials: Charles Theodore Dotter, 1920-1985. Am J Roentgenol 1985;144:1321-3.

⁶¹King SB III. Angioplasty from bench to bedside to bench. Circulation 1996;93:1621-9.

John Jones Surgical Society Day

Ensuring the Future of Our Discipline: "Stump the Professor"

Alumni associations necessarily honor the past, but the JJSS has always had a Janus character, with equal interest in doing what is within our means to support our Surgical Department's leading position in a viable and respected discipline. We do this by participating in the students' Whipple Society activities, regularly inviting them to our meetings, and, most importantly, by continuing to seek broader funding for our John Jones Research Fellowship. When talk about life-style issues, restricted work hours, and the actuality of being caught in a vice between increasing practice costs and decreased reimbursement gets you down, spend a little time with today's medical students. They are bright, challenging, and inspirational. Students now have a voice in how they are taught, and its affect is nowhere more evident than in the quality and tenor of contemporary third-year surgical clerkships.

Ten third-year students lined up to stump Professors Jeffrey Cohen, PH Chief Resident in 1987; Sherman Bull, 1968; Herb Mendel, 1983; and Rich Nitzberg, 1983. The presentations were crisp, well illustrated, and bolstered by clue-depriving dead pan expressions as

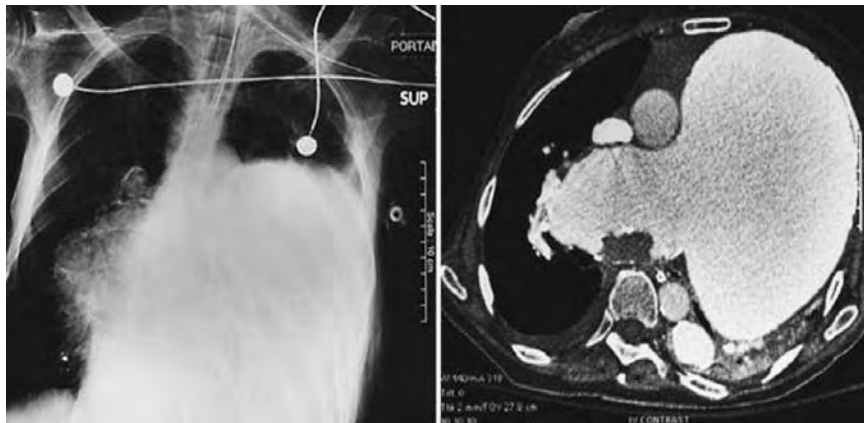


Telling professorial facial expressions and body language: Terror (HM), personally wounded (SB), eager and willing to learn (RN), and clearly stumped (JC)!



Sandy Charles after presenting a 45 year old man's acute onset of abdominal pain and shock which occurred while lifting an air conditioner (due to a ruptured visceral artery aneurysm).

the quandaries unfolded. When the diagnosis became apparent, or, despite their eminent qualifications, the panel caved, each student was ready with a concluding slide summarizing the condition. The final score was subject to some dispute, most recalling it as Students 7, faculty 3, with a few 8:2 dissenters, and absolute consensus for a 2009-return engagement. The students would not want you to miss out on the fun: here is an example of what they characterized as "unusual forms of common pathologies."



This 66 year old woman has had severe pulmonary hypertension for 20 years. In recent months, she has developed progressive shortness of breath, weakness, and deteriorating mentation. There is a 2nd left intercostal space anterior systolic impulse. ABGs on nasal O₂: pH 7.14, pCO₂ 175, pO₂ 88. (John Jones's sister is practically sitting on the diagnosis.)

Having experienced at least their bright and challenging traits, they owe you a glimpse of the educational experience that they have just completed. Clerkship Director and, in the present instance, "Head Coach" Warren Widmann writes that CUMC's 3rd-year general surgery clerkship is offered off-site at Stamford Hospital, Mary Imogene Bassett in Cooperstown, and St. Luke's-Roosevelt Hospital, and on site, where students are assigned to Milstein, MSCHONY, or the Allen Pavilion. The most sought after units are the Bassett and the Milstein Building. Students aiming at a surgical career tend to favor the latter, as "the word on the street" is that it offers potential for obtaining a "more powerful" residency recommendation. All sites integrate students into faculty-preceptor resident-physician-teams, comprising 1-3 attendings, 3-4 residents and up to 4 students. Students assume responsibility for pre- and post-operative care of their patients and assist in operations. They have a voice in the teams' conferences, and participate in out-patient visits, emergency room consultations, and night call (one night in four). Exit interviews suggest that nearly all students believe their clinical skills improved, their

ideas and questions were well received, and, that they, in turn, received appropriate feedback throughout the rotation. Oral examination performances typically endorse their personal assessments of emerging clinical acumen. The examining is all done within the Department at CUMC, and composite site-specific grades suggest equivalent across-the-board learning.

Technological Innovations Catheter and Computer-imaging Based Endovascular Procedures

Endovascular Aortic Aneurysm Repair "EVAR"



Michael Marin

Michael Marin, the Julius H. Jacobson, II Professor, and Chairman of Surgery at Mount Sinai School of Medicine, and Tim Chuter, Director of Endovascular Surgery at the University of California in San Francisco, presented EVAR's 18-year clinical history and current status. Both were Presbyterian Hospital Chief Surgical Residents in 1990, when Juan Carlos Parodi of Buenos Aires performed his paradigm-changing, endovascular aortic aneurysm exclusion. Marin began by paying homage to Presbyterian's mid-20th Century vascular doyens and pointing out that Parodi's seminal EVAR had not arisen *de novo*. Alexander Balko et al⁶² at Brown University used intraluminal covered stent-grafts to exclude false aortic aneurysms from the circulation in 1986. The experimental protocol was wholly surgical. They produced a false aneurysm by incising a sheep's aorta longitudinally from 1 cm below the renal arteries to 1 cm above the aortic trifurcation, suturing the lumbar artery orifices, and closing the incision with a 6 x 9 cm triangular polyester patch. Four weeks later, the aorta was re-exposed prior to inserting a polyurethane covered, self-expanding wire frame stent, sheathed in a 15F catheter through the femoral artery. Placement within the aorta was monitored by palpating above the aneurysm's neck for the catheter tip and the expanding stent graft as it was being ejected from the catheter. Aneurysm exclusion was confirmed by incising the polyester graft and encountering no bleeding, while good pulsations were present in the iliac arteries.

Prophetically, 13 months later, the Diagnostic Radiology Group at M. D. Anderson Hospital, which included Cesar Gianturco, reported using a stack of his stents to support an intraluminal polyester graft in normal dog aortas.⁶³ The stent stack was longer than the polyester to have bare stent extensions at both ends for anchoring. The diameter of the tube was larger than that of the aorta, so it pleated between contacts dictated by the stent wires. A proliferative reaction filled in these gaps, occluding all branch vessels within the covered area; whereas, branches, such as renal arteries, which were spanned by the bare extensions remained patent. Their approach was entirely radiologic: they had no aneurysm, but their eventual goal was aneurysm exclusion, and their findings were encouraging.

In 1988, Parodi, who had struggled in the experimental laboratory with homemade wire supports for several years, obtained some stents from fellow Argentinean and pioneering interventional radiologist, Julio Palmaz, then and now at the University of Texas, in San Antonio. Larger Palmaz stents solved Parodi's problem. His first patient was a 70 year old friend of Argentina's President with severe chronic obstructive pulmonary disease, back pain, and a large infrarenal aortic aneurysm. Palmaz came down to do the procedure with

Parodi, which was performed on September 6, 1990.⁶⁴ Consenting the patient and his family had to include something like: "We have done these grafts in 43 dogs. We think we are ready to transfer what we have learned to the clinical setting, but you are giving consent for a procedure that has never been done before in a human patient." The aneurysm originated well below the renal arteries and extended into the common iliac arteries. The graft was a straight non-crimped Dacron tube with a single, balloon-expandable stent sewn into its proximal end so that two-thirds of the stent extended beyond the polyester to anchor the graft and seal the covered end to the "normal" aorta above the graft. The patient survived for 9 years, but expansion of the proximal neck necessitated placing a longer graft inside of the first one.

Issues that had to be surmounted for EVAR to become widely applicable were immediately apparent. The insertion profile needed to be smaller, and the aorta's bifurcation and essential branch arteries had to be accommodated, as well as an inherent tendency for the graft to migrate distally. The theoretic disconnect of depending on outward force for graft stability in treating a pathological process hallmarked by expansion elicited relatively little concern. This flew in the face of contemporary increasing awareness of para-anastomotic aneurysms following open aneurysm repairs.⁶⁵



Tim Chuter

These early times were characterized by individual physician rather than industry innovations. Tim Chuter⁶⁶ was the first to address the need for a bifurcated aortic endograft; in fact, his article is number 3,060 among a June 8, 2008 total of 3,064 Pub Med endovascular aneurysm repair citations, in which number 1 is always the most recent entry. His solution involved bilateral femoral artery access, inserting a single-unit bifurcated graft into the aorta through one femoral artery, anchoring the graft's upper end, and then unfurling the second limb down the non-delivery side. The distal ends of both iliac graft limbs were then fixed in place with stents inserted through their respective ipsilateral arteriotomies. The procedure's publication in *Surgical Endoscopy* is a reminder of vascular surgery's initial hesitancy to embrace endovascular management of abdominal aneurysms.

Pre-procedural planning was greatly facilitated when Stanford radiologists Rubin and Dake⁶⁷ introduced three dimensional Spiral CT angiographic imaging constructions. Barbs supplemented outward pressure and friction to lessen the potential for distal migration. Later on, full-length stenting, modular-limb bifurcation grafts, and branch grafting enhanced aortic graft stability.⁶⁸ Bare stent crossing of renal arteries for fixation of juxta-renal aneurysm endografts became supplanted by customized fenestrations in the covering of longitudinally supported grafts. Chuter⁶⁹ remains at the forefront of computer designed customized grafts, using components from many sources. This art form reaches a zenith of design and insertion complexity in treating thoracoabdominal aneurysms.

⁶²Balko A, Piasecki GJ, Shah DM, Carney WI, Hopkins RW, Jackson BT. Transfemoral placement of intraluminal polyurethane prosthesis for abdominal aortic aneurysm. *J Surg Res* 1986;40:305-9.

⁶³Lawrence DD, Jr, Charmsangavej C, Wright KC, Gianturco C, Wallace S. Percutaneous endovascular graft: experimental evaluation. *Radiology* 1987;163:357-60.

⁶⁴Parodi JC, Palmaz JC, Barone HD. Transfemoral intraluminal graft implantation for abdominal aortic aneurysms. *Ann Vasc Surg* 1991;5:491-9.

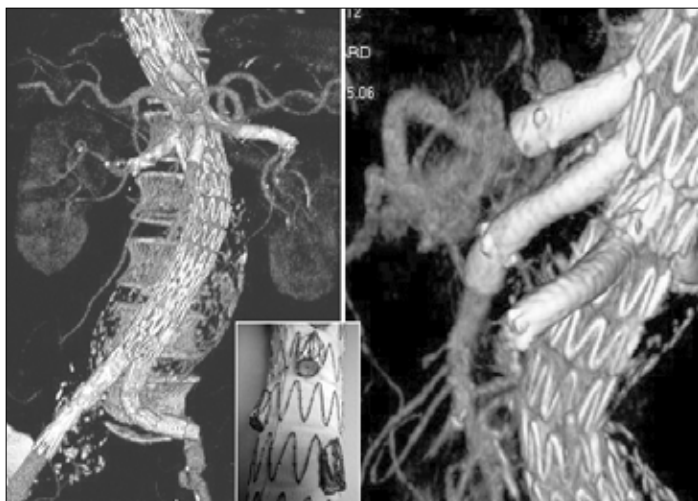⁶⁵Allen RC, Schneider J, Longenecker L, Smith RB, III, Lumsden AB. Paraanastomotic aneurysms of the abdominal aorta. *J Vasc Surg* 1993;18:424-32.

⁶⁶Chuter TA, Donayre C, Wendt G. Bifurcated stent-grafts for endovascular repair of abdominal aortic aneurysm. Preliminary case reports. *Surg Endosc* 1994;8:800-2.

⁶⁷Rubin GD, Walker PJ, Dake MD, et al. Three-dimensional spiral computed tomographic angiography: an alternative imaging modality for the abdominal aorta and its branches. *J Vasc Surg* 1993;18:656-64.

⁶⁸Benharash P, Lee JT, Abilez OJ, Crabtree T, Bloch DA, Zarins CK. Iliac fixation inhibits migration of both suprarenal and infrarenal aortic endografts. *J Vasc Surg* 2007;45:250-7.

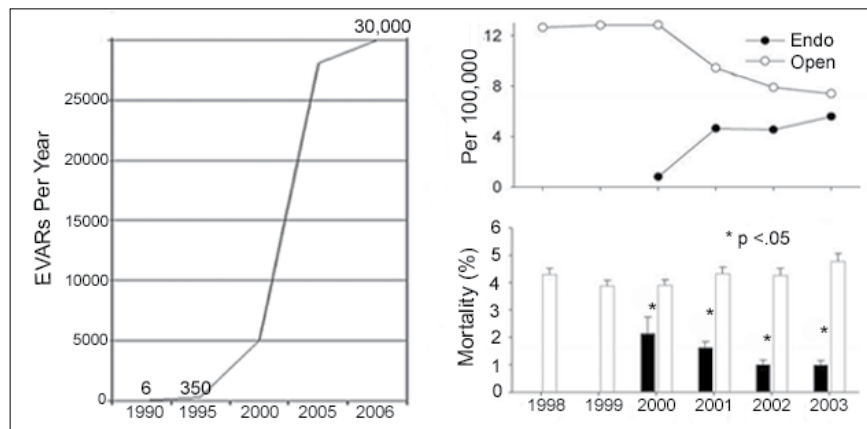
⁶⁹Chuter TAM, Rapp JH, Hiramoto JS, Schneider DB, Howell B, Reilly LM. Endovascular treatment of thoracoabdominal aortic aneurysms. *J Vasc Surg* 2008;47:6-16.



PA and lateral 3-dimensional reconstructions of a multi-branched thoracoabdominal aneurysm repair. Inset shows mid-aortic cuff-bearing graft segment.

Perhaps, it is too soon to know, but EVAR has typically not given rise to “para-implant” aneurysms. In fact, it has become the preferred approach for treating para-anastomotic aneurysms.⁷⁰ Commercially available grafts have come into their own, and, in several instances, gone away. They have not been able to meet the needs for every clinical situation, nor has the FDA been receptive to Humanitarian Device Exemptions for limited-use graft designs. Yet, there has been an astounding growth in EVAR procedures with an inflection point in the year 2000 when data indicated that 30-day EVAR mortality was significantly less than that following open repair.

A bewildering array of pronounceable-acronym studies compare a variety of commercial grafts with open aneurysm repair or even no treatment in older individuals. Individual observational series have follow up intervals up to 10 years, but newer graft designs function better than old designs, subverting the relevance of long-term data.⁷¹ EVAR also has its own lexicon that adds to the bewilderment, including, among other things, five different types of endoleaks. Referring physicians and their patients can now turn to the New England Journal of Medicine for two nicely illustrated articles that present a reasonably balanced summary of the state of the art in 2008, even though one is authored by the Principal Investigator of a debate provoking study.^{72,73} The first of these is a matched cohort study of Medicare patients undergoing EVAR or open aneurysm repair



Endovascular AAA repair growth and reciprocal decrease in open repairs driven by a significant and persistent operative mortality differential once EVAR case volume reached 5,000 per year [adapted in part from the Nationwide Inpatient Sample (NIS)].

between 2001 and 2004 with nearly 23,000 patients in each cohort. It concludes that EVAR is associated with lower short-term rates of deaths and complications. The differential in death rates is amplified in older aged patients. Later interventions for aneurysm related events were more common with EVAR, but offset by a greater number of laparotomy-related interventions and hospital admissions in the open repair cohort. The second article summarizes the larger clinical trials and the limitations of EVAR, emphasizing the need for life-long surveillance.



Roman Nowygrod

Lower Extremity Revascularization

CUMC professor Roman Nowygrod (PH Chief Resident, 1976) presented a series of 1000 procedures performed between 2001 and 2006 at NewYork Presbyterian Hospitals on both sides of Manhattan.⁷⁴ The data included 856 primary interventions and 144 reinterventions after a loss of primary patency. Among the primary procedures 43% were done for claudication and 53% for limb threatening

ischemia, with significantly more treatment extensions into the tibial arteries in the later group (51% vs. 17%). More than 94% of treated lesions were TASC (Trans Atlantic interSociety Consensus) class B-D (single stenosis > 3 cm to complete occlusion) for both claudicant and ischemic limbs. Treatments included balloon angioplasty, cryoplasty, stenting, and laser or mechanical (Silverhawk™) atherectomies, and were all done by members of the vascular surgery division.

At 2 years, overall Kaplan-Meier primary patency was 50%. Secondary procedures brought that up to 68%, and the salvage rate for threatened limbs was 79%. Reduced primary patency was significantly associated with limb threatening ischemia, diabetes mellitus, coronary artery disease, and occlusive (TASC class D) lesions. These patency rates are less than those reported for autogenous vein bypass from comparable academic vascular services. The agony is also less and more palatable for claudicants. Unlike with open procedures,

failure does not appear to prejudice the success of a subsequent revascularization, as judged by equivalent Kaplan-Meier durability for primary and secondary interventions. Although, as the figure on the next page shows, there has not exactly been a rush to judgment, endovascular disobliteration is reasonable first-line therapy for chronic lower extremity ischemia. Industry is certainly betting this way. The Pathway Medical PV™

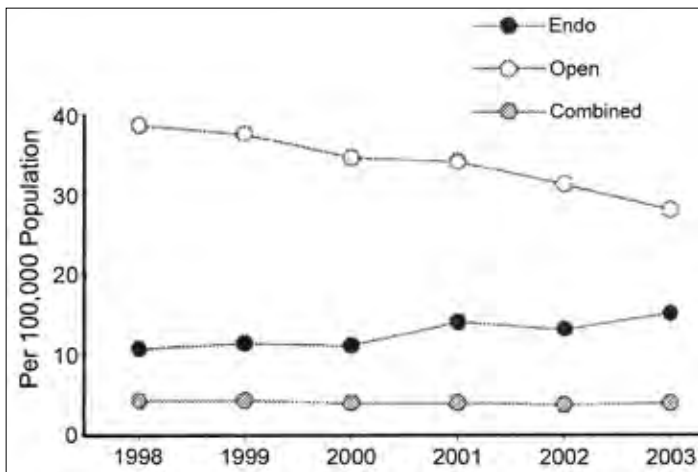
⁷⁰Sachdev U, Baril DT, Morrissey, NJ. Endovascular repair of para-anastomotic aortic aneurysms. J Vasc Surg 2007;46:636-41.

⁷¹Väärämäki S, Pimenoff G, Heikkinen M, et al. Ten-year outcomes after endovascular aneurysm repair (EVAR) and magnitude of additional procedures. Scand J Surg 2007;96:221-8.

⁷²Schermerhorn ML, O'Malley AJ, Jhaveri A, Cotterill P, Pomposelli F, Landon BE. Endovascular vs. open repair of abdominal aortic aneurysms in the Medicare population. N Engl J Med 1998;358:464-74.

⁷³Greenhalgh RM, Powell JT. Endovascular Repair of Abdominal Aortic Aneurysm. NEJM 2008;358:494-501.

⁷⁴DeRubertis BG, Faries PL, McKinsey JF, et al. Shifting paradigms in the treatment of lower extremity vascular disease. Ann Surg 2007;246:415-24.



Trends in per capita lower extremity revascularization (adapted from NIS).

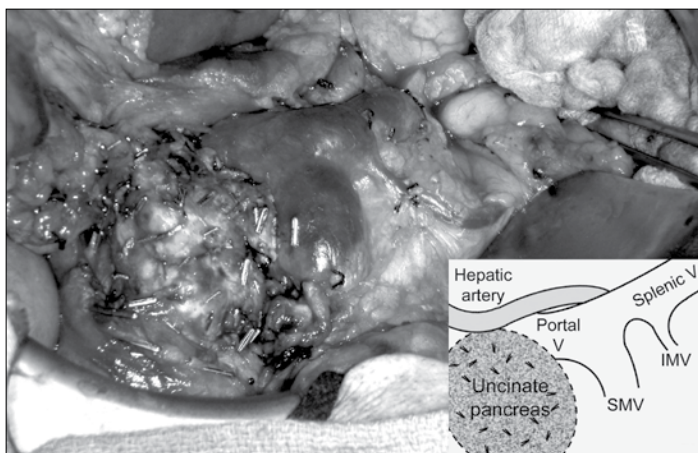
has expandable flutes for making a larger lumen, and the recently FDA cleared Diamondback 360™ aims to do the same with an eccentric abrasive crown. Work is also underway to incorporate IVUS (Intra-Vascular UltraSound) or OCT (Optical Coherence Tomography) imaging into an atherectomy device. This is a technological high hurdle, but real-time, coaxial imaging should greatly improve both accuracy and versatility.

Laparoscopic Resection of Solid Organs

The JJSS Day videos were much more interesting than the usual “Look what I did” medical movies. They spanned the spectrum of laparoscopic solid organ resection from the well accepted adrenalectomy to a right hepatectomy, which may be in the process of winning its stars. It’s not there yet, however, as judged by preference for an open operation when the chips are really down, in harvesting a portion of a living donor’s liver. John Allendorf (PH Chief Resident in 2002) tread the middle ground, showing a distal pancreatic resection. His presentation was actually upstaged by his own open partial pancreatic resection tagged on to the students’ show and tell session by Chief resident, Combiz Rezeyat. The patient had pancreas divisum



John Allendorf



Resection bed following non-laparoscopic dorsal anlage pancreatectomy.

and Intraductal Papillary Mucinous Neoplasms (IPMN), affecting just the portion of pancreas derived from the dorsal anlage, sparing the uncinata process. The operation did the same thing and appears to be a first ever.⁷⁵

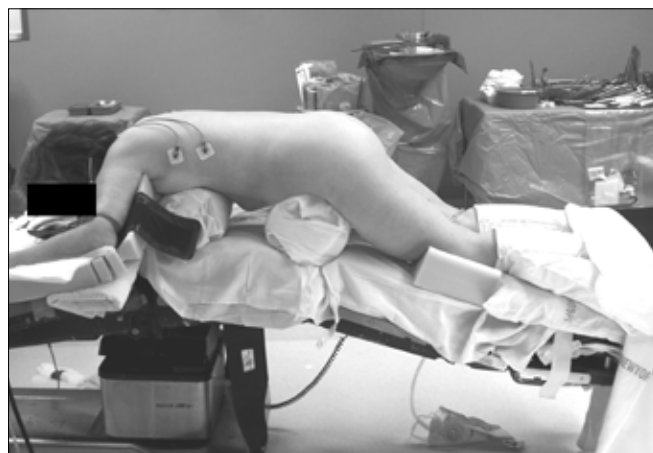Laparoscopic Adrenalectomy

Laparoscopic adrenalectomy was first described by Michel Gagner⁷⁶ in 1992. His was a trans-peritoneal operation. A New Zealand surgeon described the retroperitoneal approach two years later. Despite its obvious advantages, initially, it seemed to appeal to urologists more than general surgeons. Urologists continue to take advantage of retroperitoneal laparoscopy (a redundancy, were it not for the demise of celioscopy) for partial, total, and radical nephrectomies.



James Lee

James Lee’s video emphasized having bolsters beneath the sternum and pelvis to allow the anterior abdominal wall to sag, so that gravity can participate in development of the retroperitoneal working space. The retroperitoneal approach provides a stellar view and simplifies minimal gland manipulation, so essential to “separating the patient from the adrenal,” in pheochromocytoma or cortical malignancy cases.



Positioning for retroperitoneal laparoscopic adrenalectomy. Bolsters beneath sternum and pubis leave the anterior abdominal wall unsupported. Note compression legging and elbow and knee padding.



Andrew Gumbs

Laparoscopic Hepatectomy

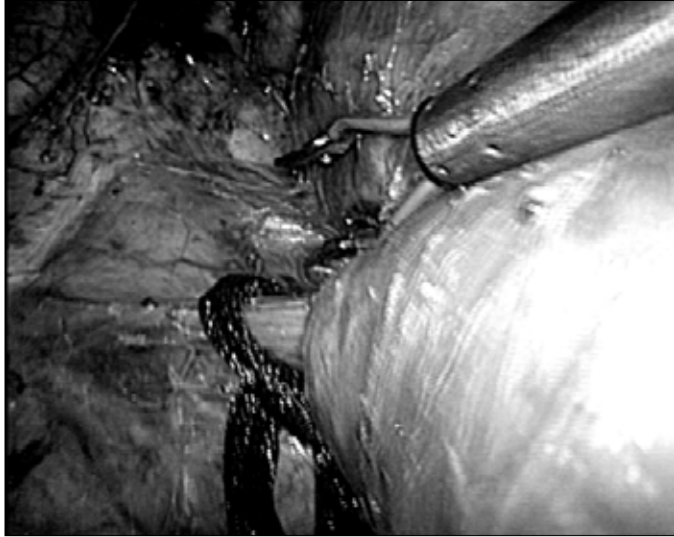
It is difficult to identify a seminal effort in laparoscopic liver resection. Simple excisions were first done in the mid-1980s, leading on to resecting larger wedges of tumor-bearing liver. The first true segmentectomy is claimed to have been performed by Azagra⁷⁷ of Montigny-le-Tilleul, Belgium, in 1993. Andrew Gumbs showed and discussed the salient features of a laparoscopic right hepatectomy. Safe transection of the substance of the liver is facilitated by assuring a low central venous pressure to minimize hepatic vein bleeding and keeping inflation pressures around 10 mmHg to minimize potential for air

⁷⁵Bassel C, Sarr MG, LillemoekD, Reber HA. Natural history of intraductal papillary neoplasms (IPMN): current evidence and implications for management. *J Gastrointest Surg* 2008;12:645-50.

⁷⁶Gagner M, Lacroix A, Bolté E. Laparoscopic adrenalectomy in Cushing’s syndrome and pheochromocytoma. *N Eng J Med* 1992;327:1033.

⁷⁷Azagra JS, Goergen M, Gilbert E, Jacobs D. Laparoscopic anatomical (hepatic) left lateral segmentectomy-technical aspects. *Surg Endosc* 1996;10:758-61.

embolism. He is fortunate to have had a fellowship with Brice Gayet at the Montsouris Institute of the University Paris, who reported on 89 laparoscopic hepatectomies in 2006, 38 of which involved resecting three or more segments. Gayet and his colleagues⁷⁸ concluded that laparoscopic and open liver resections achieve comparable results. Gumbs' excellent video suggests that superior visualization and advanced instrumentation, including robotic assistance, may soon tip the balance away from open dissection.



Spectacular laparoscopic, head-to-the-left view of middle (grasper bracketed) and right hepatic (traction ligature) veins entering IVC immediately beneath diaphragm, achieved by low pressure (10mmHg) pneumoperitoneum and patient being in steep Fowler's ("reverse Trendelenberg") position - "the hanging liver."

Natural Orifice Trans-Endoscopic Surgery "NOTES"



Marc Bessler

Marc Bessler⁷⁹ showed his video of a single abdominal port, trans-vaginal cholecystectomy, representing a two-port deletion from his published case. The grasper introduced through the abdominal port provided traction to open up the triangle of Calot. Insufflation, illumination, visualization, dissection, transection of vessel and duct, and application of occluding clips were all done through a dual-working-channel endoscope inserted through

the posterior fornix of the vagina. Bessler's consenting speech undoubtedly bested Parodi's and was equally well witnessed. The primary flexible-shaft dissecting instruments consisted of a hinged blunt-jaw grasper and a cautery hook. Currently available endoscopic clips are occlusive only at their tips, as they were designed for clamping down on superficial bleeding points. Consequently, multiple clips were needed to assure occlusion of the cystic artery and duct with a back-up plan to introduce a laparoscopic clip applier if necessary. As observed on the video, visualization was excel-

lent, dissection progressed nicely, and the endoscopic clips worked well. Natural orifice surgery is not new: neurosurgeons have been performing trans-nasal, trans-sphenoidal operations on the pituitary for years, but double-instrument dissecting to isolate, transect and clamp structures through a flexible endoscope is indisputably novel.

Who Should be (and is) Doing What FOR Whom?

NOTES is an ideal segue into this topic: it is highly controversial and has potential to facilitate "non-surgeons" doing "surgery." NOTES is now about where catheter and image based vascular interventions were in 1995, when Frank Veith et al⁸⁰ chaired a Guidelines Committee to address the non-parenthetic portion of this section's title. "et al" included Dorothy Abel from the Food and Drug Administration, Mike Dake, Barry Katzen, and other interventionalists. The Committee's report was published simultaneously in *Vascular Surgery* and *Vascular Interventional Radiology* and unambiguously advocated an interdisciplinary team approach.

In like manner, but earlier in the process, Dave Rattner⁸¹ from SAGES and Anthony Kalloo from the American Society of Gastrointestinal Endoscopists used their respective journals to notify colleagues of a joint plan for NOTES' development. The authors had formed a Natural Orifice Surgery Consortium for Assessment and Research (NOSCAR). They invited physicians from both disciplines who were willing to do responsible research and share their work at semi-annual group meetings to join. They also proposed to use the good offices of both Societies to obtain research funding and encourage industry to develop enabling new tools.⁸² At the time, a single presentation of a human transgastric appendectomy had been made, but only pig work had been published.

The latter included a provocative report by Kalloo and his Johns Hopkin's colleagues⁸³ describing peroral, transgastric peritoneoscopy and liver biopsies in five pigs, which were eating regular chow 24 hours later. They found micro abscesses in the first two pigs when they were euthanized at two weeks. They lavaged the stomach with antibiotic solution before endoscopy in the next three and observed no further intra-peritoneal abscesses or positive cultures. The gastrotomies were closed with the same endoscopic clips used by Bessler, working from the ends of the incision towards the center. The clips were gone when the animals were re-endoscoped at two weeks. The gastrotomies were essentially unidentifiable from within and well healed at autopsy.

Despite biting critical comments from prominent laparoscopic surgeons, NOSCAR has accomplished what it set out to do as evidenced by a third International Symposium on NOTES that will take place in San Francisco on July 10, 2008.⁸⁴ NOSCAR has done nothing to preclude full participation by gastroenterologists and does not appear to have any intention of doing so. NOTES changes the incision site, hiding it from the patient's view and potentially placing it where there would be no post-procedure incision pain. More importantly, it frees the operator from having fixed instru-

⁷⁸Vibert E, Perniceni T, Levard H, Denet C, Shahri NK, Gayet B. Laparoscopic liver resection. *Br J Surg* 2006;93:67-72.

⁷⁹Bessler M, Stevens PD, Milone L, Parikh M, Fowler D. Transvaginal laparoscopically assisted endoscopic cholecystectomy: a hybrid approach to natural orifice surgery. *Gastrointest Endosc* 2007;66:1243-5.

⁸⁰Veith FJ, Abbott WM, Yao JST, et al. Guidelines for development and use of transluminally placed endovascular prosthetic grafts in the arterial system. *J Vasc Surg* 1995;21:670-85.

⁸¹D. Rattner, A. Kalloo, and the SAGES/ASGE Working Group on Natural Orifice Transluminal Endoscopic Surgery. *Surg Endosc* 2006;20:329-33.

⁸²Swanstrom LL, Whiteford M, Khajanchee Y. Developing essential tools to enable transgastric surgery. *Surg Endosc* 2008;22:600-4.

⁸³Kaloo AN, Singh VK, Jagannath SB, et al. Flexible transgastric peritoneoscopy: a novel approach to diagnostic and therapeutic interventions in the peritoneal cavity. *Gastrointest Endosc* 2004;60:114-7.

⁸⁴SAGES/ASGE Joint Committee. Where have we been and where are we going? *Surg Endosc* 2008;22:1143-5.

ment fulcrums in the wall of the abdomen or chest, and therein lays its real potential. “Chest” – what about all those pulmonologists; is the mediastinum part of their future?⁸⁵



George Todd

George Todd, the Walter A Wichern Jr. Professor and Chairman of Surgery at St. Luke's-Roosevelt Hospital Center (and 1979 PH Chief Resident) presented the then and now status of cooperative teamwork between vascular surgeons and vascular interventionalists. He reviewed ecumenical models proposed by both disciplines, as well as his first-hand experience at St Luke's-Roosevelt, noting that as time went on ecumenism fell apart, and

citing economic squeeze as the catalyst for dissolution.^{86,87} Todd and his fellow Vascular Renaissance presenters, save for real scientist, Dave Tilson, are personifications of an alternate, and much more attractive, interpretation. They are vascular-endovascular surgeons, at home in the catheterization laboratory, as well as in the operating suite. Their blended skill set, and knowledge of vascular disease, make them eminently suited to care for patients with vascular pathology. As a consequence, they infrequently need the assistance of an interventional radiologist. At least in other settings, the reverse is also true. Cardiologists, interventional vascular radiologists, and neuroradiologists incise arteries when they need to and close their own wounds. Hopefully, these separatist activities do not deprive patients of the combined wisdom available through interdisciplinary conferences.

The Clinical Practice Council of the Society for Vascular Surgery has put their imprimatur on vascular-endovascular surgeons, updating their advice to hospitals for credentialing.⁸⁸ Assuming patient centricity, the premise cannot be that less qualified, or more accurately, differently qualified physicians should not treat patients with vascular disease “exclusive of intracardiac and intracranial vessels.” Interventional cardiologists are important drivers of new technology and are likely to want to apply it to non-cardiac lesions. Are they less qualified to pursue developments in carotid arterial stenting when no one seems to have the real answer yet? A neuroradiologist negotiating a wire into position to insert a middle cerebral artery stent must first deal with any ipsilateral, cervical carotid stenotic plaque. His manipulations will traumatize it unless it is protected, and, if left untreated, it would place the intracranial stent at greater risk for early occlusion. Defining the boundaries of endovascular and vascular surgery is helpful to patients and referring physicians as well as hospital credentialing committees. But, who should be doing what must focus on patient welfare, which translates to outcomes data favoring a particular group or facility. These are hard to come by data, as they require careful risk adjustment to function as reliable better-care guides.

The Society for Vascular Surgery has addressed this need by establishing an on-line, risk-adjusted, Vascular Registry (SVS-VR) beginning with carotid artery procedures. The Centers for Medicare and Medicaid Services (CMS) mandated a carotid artery stenting

(CAS) registry of hospital outcomes as part of its National Coverage Decision for CAS. The SVS-VR went two steps further, including carotid endarterectomy (CEA) in addition to CAS, and extending follow up beyond the typically brief hospitalizations to traditional 30-day morbidity and mortality reporting. Since its inception in July 2005, 287 care providers representing seven specialty groups have contributed data on more than 2,700 CAS and nearly 3,300 CEA patients.⁸⁹ Just under half of CAS procedures and 42% of CEAs were done for symptomatic disease. The submitting specialties include cardio-thoracic, general, neuro, and vascular surgeons and cardiac, neuroradiologic, and vascular interventionalists. Data regarding specialty-specific outcomes will not be forthcoming until the sample size becomes sufficient to sustain such parsing, which is years away. Until comparable data are available for any treatment from any source, pre-emptive “no trespassing” implications contravene patient centricity.

Understanding and Mining Large, Administrative Databases

For the past three years, surgical society programs have uniformly included several presentations derived from the Nationwide Inpatient Sample (NIS), in particular, as well as other large administrative databases. The discussions that ensue are remarkably consistent. Questioners always ask for more clinical detail, and the presenter holds his or her hands palms up and responds that the requested details were not captured within the data. CUMC surgeon researchers enjoy readily available and exceptionally adept collaboration in mining large administrative data bases from Dr. Annetine Gelijns' International Center for Health Outcomes and Innovation Research (InCHOIR). Roman Nowygrod, Jim McKinsey, Nick Morrissey, James Lee, William Inabnet, Dennis Fowler, and Jean Emond have all availed themselves of this remarkable resource.

The various databases have individual advantages and limitations. The Medicare data base, for example, encompasses 41 million patients, permitting subgroup analyses while retaining sufficient power to detect meaningful differences if they indeed exist. Tracking by Social Security numbers facilitates longitudinal studies and merging with census data and the National Death Index. Data from CMS are always rendered anonymous by substituting unique study case numbers for issuance to an investigator, obviating the impossible task of obtaining informed consents. Patient age is a restrictive factor; 98% will be 65 or older, which can be a pre-selection asset in looking at EVAR vs. open repair.

Roman Nowygrod⁹⁰ probed two national data sets and one compiled from four states in looking at complications and mortality in peripheral vascular surgery. The first was the NIS, which is part of the Healthcare Cost and Utilization Project (HCUP) and encompasses data from hospital in-patient stays in 38 participating states. The HCUP-NIS sample has been conducted since 1988 and allows longitudinal analyses of national trends in medical care. It contains data from about 20% of non-federal, larger community hospitals and claims to encompass 90% of all US hospitalizations in its 2006 sample, which is the latest available. Nowygrod's other national data

⁸⁵Willingham FF, Gee DW, Lauwers GY, Brugge WR, Rattner DW. Natural orifice transesophageal mediastinoscopy and thoracoscopy. *Surg Endosc* 2008;22:1042-7.

⁸⁶Becker GJ, Katzen BT. The vascular center: a model for multidisciplinary delivery of vascular care for the future. *J Vasc Surg*. 1996 May;23(5):907-12

⁸⁷Ouriel K, Green RM, Waldman D, Greenberg RK, Shortell CK, Illig K. A model for merging vascular surgery and interventional radiology: clinical and economical implications. *J Vasc Surg* 1998;28:1006-10.

⁸⁸Calligaro KD, Toursarkissian B, Clagett GP, et al for the Clinical Practice Council, Society for Vascular Surgery. Guidelines for hospital privileges in vascular and endovascular surgery: recommendations of the Society for Vascular Surgery. *J Vasc Surg* 2008;47:1-

⁸⁹Sidaway AN, presenting on behalf of the SVS Outcomes Committee. Vascular Annual Meeting, June 6, 2008, San Diego, CA.

⁹⁰Nowygrod R, Egorova N, Greco G, et al. Trends, complications, and mortality in peripheral vascular surgery. *J Vasc Surg* 2006;43:205-16.

came from the National Hospital Discharge Survey (NHDS), which is compiled annually by the National Center for Health Statistics. It contains medical and demographic information from discharge records, selected from a national sample of acute care hospitals, excluding those with less than 6 beds, as well as all federal hospitals. The sampled hospitals comprise slightly more than 8% of US hospitals and are not constant from year to year. The data are generated by manual review of medical transcription performed by a hospital's staff or by staff of the U.S. Bureau of the Census on behalf of the NHDS and are also purchased outright from commercial organizations, State data systems, hospitals, or hospital associations.

The New York State Health Department's Statewide Planning and Research Cooperative System (SPARCS), California's Office of Statewide Planning and Development, New Jersey's Department of Health and Senior Service, and the Florida Department of Health's Florida Discharges Data Abstracts comprised the state-based sample. The trends across databases were reassuringly consistent, generally showing incremental use of catheter based endovascular procedures with a corresponding decline in open approaches. The change was most dramatic with EVAR and least for carotid arterial stenting.

Nick Morrissey⁹¹ used SPARCS and Florida's State Agency for Healthcare Administration as catchment areas for substantial Hispanic populations to assess their vascular disease treatments and outcomes. He found that Hispanics underwent significantly fewer procedures, and, although younger, were more likely to have untreated hypertension, limb threatening ischemia, symptomatic carotid stenoses, and ruptured abdominal aortic aneurysms than non-Hispanic whites.

James Lee and his colleagues⁹² queried the Veterans Affairs' National Surgical Quality Improvement Program (VA NSQUIP), looking at patient features for those undergoing laparoscopic vs. open adrenalectomies and the relative 30-day morbidity rates, when adjusted for confounding risks. Risk factor adjudication is NSQUIP's principal advantage over other databases, which permits more meaningful quality assessment across hospitals and surgeons in addressing patient and payee concerns as well as government oversight. Open procedures resulted in more pneumonia, unplanned reintubation, systemic sepsis, cardiac arrests, renal insufficiency, and surgical site infections. Overall, open procedure, unadjusted 30-day morbidity rates were almost five fold higher than those for patients who had a laparoscopic adrenalectomy. However, patients undergoing open adrenalectomies were older, more frequently smoked, had lower serum albumin levels, and were three times as likely to have malignancy. Risk adjustment reduced the odds ratio effect of the two operative approaches only slightly to 4.0, showing that the morbidity saving attributable to the laparoscopic approach was an independent significant advantage.

Dennis Fowler and Jean Emond were prominent "et als" in an InCHOIR study that looked into the accuracy of instrument and sponge counting.⁹³ The data were derived from "a major academic health care center and its affiliated hospitals' OR incidents." Reports of final discrepant OR counts were entered into Total HealthSystem's web-based, Medical Event Reporting System (MERS-TH), which is used by many hospitals for quality assurance and risk management. There were 1,062 discrepant counts from slightly more than 153,000

surgical procedures (0.7%) The missing item was found only 51 times, in 34 instances it was somewhere in the OR, and, in 17, it was in the patient. The missing item was removed from 11 of these 17 true positives before closing. There were also 5 instances without a discrepant count in which a retained foreign body was subsequently discovered. Despite its 1,045 false positives, low event prevalence still gave the counting process 99% specificity along with its 77% (17/22) sensitivity.

Abdominal Aortic Aneurysms, Molecular Screening and Green Tea



M. David Tilson, III

M. David Tilson, III, Columbia University's Alisa Mellon Bruce Professor of Surgery and former Surgical Chairman at St. Luke's-Roosevelt Hospital Center, has relentlessly pursued the complex but very influential non-syndromic⁹⁴ genetic inheritance underlying individual susceptibility to aortic aneurysms.⁹⁵ He eventually accumulated 50 families with two or more first-order relatives having an abdominal aortic aneurysm (AAA). Johansen and Koepsel⁹⁶

studied the family histories of 250 AAA probands and 250 probands with atherosclerotic aortic occlusive disease. The AAA index cases had a 19% incidence of first-order relatives with AAAs; whereas, the comparable AAA figure for the occlusive disease patients was only 2%. Kaj Johansen and his colleague were the first to suggest the obvious utilitarian implication to screen AAA patient relatives with abdominal ultrasound in 1986.

Kuivaniemi et al⁹⁷ noted that male dominance is substantially less among non-syndromic familial AAAs than that observed in sporadic cases. Familial AAA male patients are on average 5 years younger and have an unusually high 41% rupture incidence. Since the general prevalence of AAAs is 6 times greater in men, a larger aggregate of genetic liabilities may be needed for women to develop an AAA, which is true for pyloric stenosis in female infants. Female AAA patients then would be more likely than male patients to have an affected offspring, as is the case with pyloric stenosis.

The next step is to identify specific genes associated with susceptibility. There are two approaches to gene discovery, genome-wide screening and evaluating preselected candidate genes. The latter is facilitating and far less expensive but risks winding up empty-handed. Tilson and his group⁹⁸ selected three candidate genes for continued investigation. The first of these is Collagen XI-alpha-1 (COL11A1), which has 38-fold gene-chip over expression by AAA adventitial fibroblasts compared to fibroblasts from normal aorta adventitia. The second is HLA (human leukocyte antigen) DR-15 which is a known susceptibility allele in Japanese AAA patients and associated with autoimmune T-cell clones directed against collagen and elastin fibers. The third viable candidate is the light chain of ferritin (FTL), which is near a susceptibility locus for both cerebral and aortic aneurysms and has exhibited specific codon (tri-nucleotide sequence) mutations affecting protein folding and stability.

⁹¹Morrissey NJ, Giacobelli J, Egorova N, et al. Disparities in the treatment and outcomes of vascular disease in Hispanic patients. *J Vasc Surg* 2007;46:971-8.

⁹²Lee J, El-Tamer M, Schiffner T, et al. Open and laparoscopic adrenalectomy: analysis of the National Surgical Quality Improvement Program. *J Am Coll Surg* 2008;206:953-9

⁹³Egorova NN, Moskowitz A, Gelijs A, et al. Managing the prevention of retained surgical instruments: what is the value of counting? *Ann Surg* 2008;247:13-8.

⁹⁴Aside from Marfan, Ehlers-Danlos, and Loeys-Dietz syndromes

⁹⁵Wassef M, Upchurch GR Jr, Kuivaniemi H, Thompson RW, Tilson MD 3rd. Challenges and opportunities in abdominal aortic aneurysm research. *J Vasc Surg* 2007;45:192-8.

⁹⁶Johansen K, Koepsel T. Familial tendency for abdominal aortic aneurysms. *JAMA* 1986;256:1034-6.

⁹⁷Kuivaniemi H, Platsoucas CD, Tilson MD III. Aortic aneurysms: an immune disease with a strong genetic component. *Circulation* 2008;117:242-52.

⁹⁸Tilson MD III, Ro CY. The candidate gene approach to susceptibility for abdominal aortic aneurysm: TIMP1, HLA-DR-15, ferritin light chain, and collagen XI-Alpha-1. *Ann N Y Acad Sci* 2006;1085:282-90.

Now, About That Tea

Cigarettes are one of the Asia's most highly consumed products, second only to green tea consumption, yet Asia, and Japan in particular, have some of the World's lowest per capita incidences of arteriosclerosis and lung cancer. Since the Western World prefers coffee and completely fermented, black tea, this "Asian Paradox," has been hypothesized to be the effect of a protective substance in unfermented green tea.⁹⁹ The benefit of green tea becomes manifest at a regular daily consumption rate of 1.2 liters. Green tea has the highest concentration of catechins per gram of dried leaves compared to that of black and partially fermented oolong teas and is the best dietary source of these compounds. Epigallocatechin-3-gallate (EGCG) has

greater antioxidant potency than the other catechins. More specifically, it has been shown, in-vitro, to cause a dose-related reduction in AAA fibroblast lysate matrix metalloproteinase-2 activity. EGCG is marketed as AneuMastat[®] a "Nutraceutical" for promoting "vascular health." Matrix metalloproteinases and their inhibitors have been one of Dave's consuming interests for more than 30 years. Not surprisingly, the St. Luke's-Roosevelt group put 250mg/kg/day of AneuMastat in the drinking water of mice in which topical CaCl₂ had been used to induce abdominal aortic aneurysm formation.¹⁰⁰ At 4 weeks post-induction, aortas in mice drinking untreated water increased in diameter as expected, but significant expansion was not found in the EGCG drinkers. Surely, a follow-up report must be right around the corner.

John Jones Surgical Society Day



Symposium presenters - Jim Chandler, Jim McKinsey, Dave Tilson, Tim Chuter, Jack Jacobson, Nick Morrissey, George Todd and Roman Nowygrod




Ken Forde and Tom King,
José M. Ferrer Professors Emeriti



Jack Jacobson and JB Price



Sherman Bull, John Kinney and Ken Forde



P&S students: Wassim Abida, Sandy Charles, Samuel Ash, Nancy Chen, Andrew Bellinger, Xavier Simcock and Jeanne Franzone



Warren Widmann with Foster Conklin

⁹⁹Sumpio BE, Cordova AC, Berke-Schlessel DW, Qin F, Chen QH. Green tea, the "Asian Paradox," and cardiovascular disease *J Am Coll Surg* 2006;202:814-25.

¹⁰⁰Ro CY, Fukumoto R DeRose JJ Jr, et al. AneuMastat prevents aneurysm formation in a murine model of abdominal aortic aneurysm (AAA). *J Am Coll Surg* 2006;203:S103.



Joseph Kessler and John Schullinger



Dave Carberry and Robert Mulcare



Ken Forde and Fred Jaretski

Reception and Dinner at the NYAC



Alan Benvenisty and Dave Tilson



Andrea Scafuri, Jeff Cohen, Diane and Larry Whelan, Jody King, Allison McLarty and Tom King



Kit Barker and Mark Hardy



Tim Chuter and Larry Whelan



Hal Barker, Dick Edie and Dave Carberry



Henry and Sharon Spotnitz



Carey Dolgin and Ellen Steiner Dolgin,
Herb and Ilene Mendel



Joan Jacobson, Sherman and Peggy Bull



Diana Gelfand, Mark and Ruth Hardy



Michael Gelfand and Eric Liu



Paul Gerst with Seena Cowan (left) and Myra Widmann



Peggy Bull, Foster Conklin, Cindi Chandler, Sherman Bull, Jim Chandler, Jonathan Roach, John and Nancy Schullinger



Seated: John Chabot, Gary Tannenbaum and Terri McKinsey. Standing: David Johnstone, Tim Chuter, Larry Jordan, Jim McKinsey and Bob Grant

The John Jones Surgical Society 2008 Reception

*94th Annual Clinical Congress
of the American College of Surgeons*

Westin St. Francis Hotel, San Francisco, California

*Tuesday, October 14th
6pm - 8pm*

John Jones Surgical Society

177 Fort Washington Avenue, MHB 7SK

New York, NY 10032

Telephone: 212-305-2735

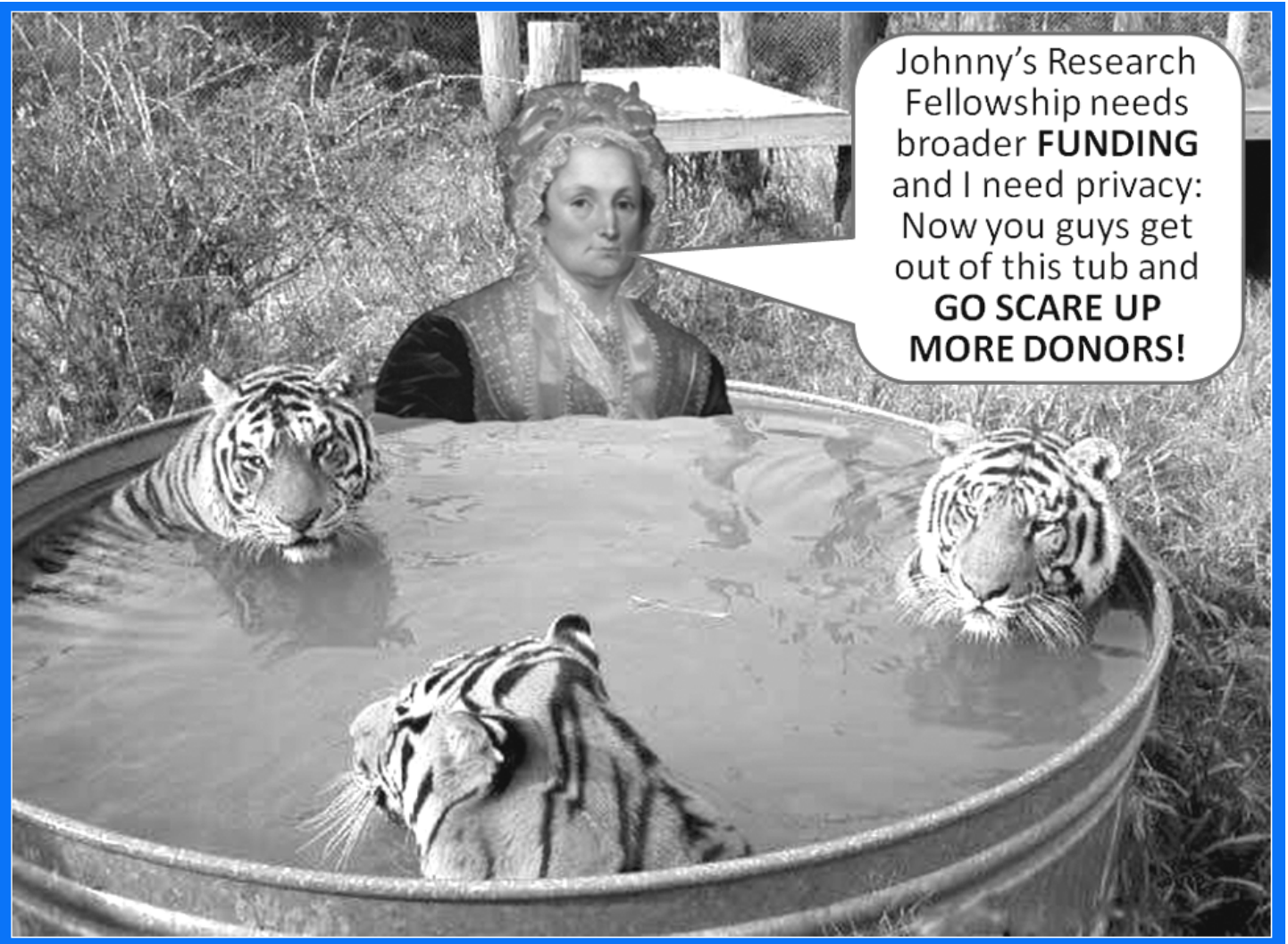
Fax: 212-305-3236

webpage: www.columbiasurgery.org/alumni/index.html

Editor: *James G. Chandler*

Administrator: *Trisha J. Hargaden*

Design: *Columbia University Center for Biomedical Communication*



Make your check payable to Columbia University and write John Jones Research Fellowship on the memo line and mail it to William J. Horan, Senior Director of Development, Columbia University, College of Physicians & Surgeons, 100 Haven Avenue, Suite 29D, New York, NY 10032. Telephone or e-mail Bill at 212-544-1920 or wjh2104@columbia.edu to assure that your contribution goes to the JJRF, or with any questions you might have.

“Stump the Professor”

**Pulmonary
artery
aneurysm**

Note contrast-filled burlesque of the pulmonary artery, posterior to both the ascending aorta and superior vena cava, and anterior to bifurcating trachea, compressed esophagus, and descending aorta. There is massive encroachment on the perfused left lung's ventilation, accounting for the whopping pCO_2 . PAAs are associated with congenital left-to-right shunting, trauma, infections (syphilis), or vasculitis (Behçet's syndrome).